



Spectrum of neurological complications following COVID-19 vaccination

Ravindra Kumar Garg¹ · Vimal Kumar Paliwal²

Received: 4 August 2021 / Accepted: 8 October 2021 / Published online: 31 October 2021
© Fondazione Società Italiana di Neurologia 2021

Abstract

COVID-19 vaccines have brought us a ray of hope to effectively fight against deadly pandemic of COVID-19 and hope to save lives. Many vaccines have been granted emergency use authorizations by many countries. Post-authorization, a wide spectrum of neurological complications is continuously being reported following COVID-19 vaccination. Neurological adverse events following vaccination are generally mild and transient, like fever and chills, headache, fatigue, myalgia and arthralgia, or local injection site effects like swelling, redness, or pain. The most devastating neurological post-vaccination complication is cerebral venous sinus thrombosis. Cerebral venous sinus is frequently reported in females of childbearing age, generally following adenovector-based vaccination. Another major neurological complication of concern is Bell's palsy that was reported dominantly following mRNA vaccine administration. Acute transverse myelitis, acute disseminated encephalomyelitis, and acute demyelinating polyneuropathy are other unexpected neurological adverse events that occur as result of phenomenon of molecular mimicry. Reactivation of herpes zoster in many persons, following administration of mRNA vaccines, has been also recorded. Considering the enormity of recent COVID-19-vaccinated population, the number of serious neurological events is miniscule. Large collaborative prospective studies are needed to prove or disprove causal association between vaccine and neurological adverse events occurring vaccination.

Keyword COVID-19; SARS-COV-2; Vaccination; Cerebral venous sinus thrombosis; Thrombocytopenia

SARS-CoV-2 is a novel coronavirus that can rapidly affect human beings and can result in coronavirus disease (COVID-19). COVID-19 is dominantly characterized by lung damage and hypoxia. The first case of COVID-19, in Wuhan, China, was reported on December 8, 2019. Later, the World Health Organization announced COVID-19 as a worldwide health emergency, on January 30, 2020. On March 11, 2020, COVID-19 was declared a pandemic. As per the latest World Health Organization report, there were 196,553,009 confirmed cases as on August 1, 2021 along with 4,200,412 deaths [1].

Early this year, COVID-19 vaccines has brought a ray of hope to effectively fight against this deadly pandemic and save precious human lives. Currently, four major vaccine types are being used. These vaccine types include viral vector-based vaccines, COVID-19 mRNA-based vaccines, inactivated or attenuated virus vaccine, and protein-based vaccines. In viral vector-based vaccines, adenovirus is used to deliver a part of SARS-COV-2 genome to human cells. Human cells use this genetic material to produce SARS-COV-2 spike protein. Human body recognizes this protein to start a defensive response. The mRNA-based vaccines consist of SARS-COV-2 RNA. Once introduced, genetic material helps in making SARS-COV-2-specific protein. This protein is recognized by human body to start defensive immune reaction. In inactivated or attenuated vaccines, killed or attenuated SARS-COV-2 virus triggers immune response. Protein-based vaccines use the spike protein or its fragments for inciting immune response. These COVID-19 vaccines have received emergency approvals in different countries for human use [2]. As per the latest World Health Organization report, until August 1, 2021, globally, a total

✉ Ravindra Kumar Garg
garg50@yahoo.com
Vimal Kumar Paliwal
dr_vimalkpaliwal@rediffmail.com

¹ Department of Neurology, King George Medical University, Lucknow, Uttar Pradesh, India PIN-226003

² Department of Neurology, Sanjay Gandhi Postgraduate Institute of Medical Sciences, Rae Bareilly road, Lucknow, India

of 3,839,816,037 COVID-19 vaccine doses have been globally administered [1].

In fact, all kinds of vaccines are associated with the risk of several serious neurological complications, like acute disseminated encephalomyelitis, transverse myelitis, aseptic meningitis, Guillain-Barré syndrome, macrophagic myofasciitis, and myositis. Influenza vaccine has been found associated with narcolepsy in young persons. Several pathogenic mechanisms, like molecular mimicry, direct neurotoxicity, and aberrant immune reactions, have been ascribed to explain these vaccines associated with neurological complications [3]. Even COVID-19 vaccines are not free from neurological complications. In this article, we have focused on the neurological complications following COVID-19 vaccination that were reported after their emergency use authorizations.

Search strategy

We reviewed available data regarding neurological complications (post-authorization) described following the World Health Organization–approved COVID-19 vaccination. We classified COVID-19 vaccination associated with neurological complications in two broad groups: (1) common but mild and (2) rare but severe. We searched PubMed, Google, and Google Scholar databases using the keywords “COVID-19” or “SARS-CoV-2” and “vaccination” or “vaccine,” to identify all published reports on neurological complications of COVID-19 vaccines. We in this review will focus on spectrum of published neurological adverse events following COVID-19 vaccination. Last search was done on August 1, 2021.

Mild neurological events

Neurological adverse events following COVID-19 vaccination are generally mild and transient, like fever/chills, headache, fatigue, myalgia and arthralgia, or local injection site effects like swelling, redness, or pain. These mild neurological symptoms are common following administration of all kinds of COVID-19 vaccines.

Anxiety-related events, like feeling of syncope and/or dizziness, are particularly common. For example, Centers for Disease Control and Prevention, in a report published on April 30, 2021, recorded 64 anxiety-related events (syncope in 17) among 8,624 Janssen COVID-19 vaccine recipients. None of the event was labeled as serious [4].

In Mexico (data available in form of preprint) among 704 003 subjects who received first doses of the Pfizer-BioNTech mRNA COVID-19 vaccine, 6536 adverse events following immunization were recorded. Among those, 4258 (65%) had

at least one neurologic manifestation, mostly (99.6%) mild and transient. These events included headache (62.2%), transient sensory symptoms (3.5%), and weakness (1%). In this study, there were only 17 serious adverse events, seizures (7), functional syndromes (4), Guillain-Barré syndrome (3), and transverse myelitis (2) [5].

In South Korea, Kim and co-workers collected data of post-vaccination adverse events following first dose of adenovirus vector vaccine ChAdOx1 nCoV-19 (1,403 subjects) and mRNA vaccine BNT162b2 (80 subjects) vaccinations. Data were collected daily for 7 days after vaccination. Authors noted that 91% of adenovirus-vectored vaccine and 53% of mRNA vaccine recipients had mild adverse reactions, like injection-site pain, myalgia, fatigue, headache, and fever [6]. A mobile-based survey among healthcare workers (265 respondents) who received both doses of the BNT162b2 mRNA vaccine was conducted. The most common adverse effects were muscle ache, fatigue, headache, chills, and fever. Adverse reactions were higher after the second dose compared with that after the first dose [7].

Headache

Headache is one of the most frequent mild neurological complaints reported by a large number of COVID-19 vaccine recipients, soon after they receive vaccine.

A review of headache characteristic noted that among 2464 participants, headache begun 14.5 ± 21.6 h after AstraZeneca adenovirus vector vaccine COVID-19 vaccination and persisted for 16.3 ± 30.4 h. Headaches, in majority, were moderate to severe in intensity and generally localized to frontal region. Common accompanying symptoms were fatigue, chills, exhaustion, and fever [8]. In a multicenter observational cohort study, Göbel et al. recorded clinical characteristic of headache occurring after the mRNA BNT162b2 mRNA COVID-19 vaccination. Generally, headache started 18.0 ± 27.0 h after vaccination and persisted for 14.2 ± 21.3 h. In majority, the headaches were bifrontal or temporal, dull aching character and were moderate to severe in intensity. The common accompanying symptoms were fatigue, exhaustion, and muscle pain [8].

Severe neurological adverse events

Serious adverse reaction following immunization is defined as a post-vaccination event that are either life-threatening, requires hospitalization, or result in severe disability. The World Health Organization listed Guillain-Barré syndrome, seizures, anaphylaxis, syncope, encephalitis, thrombocytopenia, vasculitis, and Bell’s palsy as serious neurologic adverse events. Instances of serious adverse events following COVID-19 vaccinations are continuously pouring in the

current scientific literature and are source of vaccine hesitancy in many persons [9] (Fig. 1).

Functional neurological disorders

Functional neurological disorders are triggered by physical/emotional stress following an injury, medical illness, a surgery, or vaccination. Functional neurological disorders often remain misdiagnosed despite extensive workup.

After availability of COVID-19 vaccine, many YouTube videos depicted continuous limb and trunk movements and difficulty walking immediately after COVID-19 vaccine administration. These videos were of concern as they were the source of “vaccine hesitancy” [10]. Kim and colleagues reviewed several such social media videos demonstrating motor movements consistent with functional motor symptoms occurring after administration of COVID-19 vaccine. Motor movements were bizarre asynchronous and rapidly variable in frequency and amplitude consistent with functional neurological disorder. The Functional Neurological Disorder Society has lately clarified that movement disorder is consistent with functional in nature. The spread of these videos are important because these functional disorders created concerns for vaccine hesitancy [11].

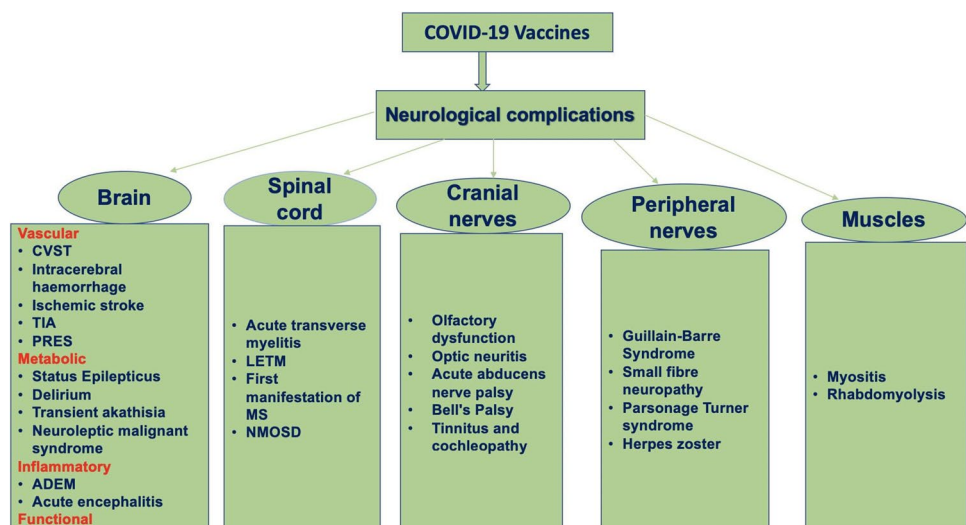
Several other kinds of functional neurological disorders have also been reported. Butler and colleagues described two young ladies, who presented with functional motor deficits mimicking stroke. Both these patients had variability in weakness and had many non-specific symptoms. A detailed workup and neuroimaging failed to demonstrate any specific abnormality [12]. Ercoli and colleagues described a middle-aged man who, immediately after vaccine administration, reported bilateral facial paralysis along with failure to blink. These manifestations resolved quickly within 40 min. Immediately after administration of second dose of vaccine,

he complained of respiratory distress and swollen tongue. Again, all these symptoms resolved quickly following treatment with corticosteroids, however, he developed new symptoms in the form of right hemiparesis. Two weeks later, he developed facial hypoesthesia. A detailed workup of the patient failed to demonstrate any abnormality. A diagnosis of functional neurological disorder was, finally, made [13].

Cerebral vascular events

As a matter of concern, increasing number of reports about adenoviral vector vaccine-induced cerebral vascular adverse events, like cerebral venous thrombosis, arterial stroke, and intracerebral hemorrhage, is getting published in leading medical journals. These reports are alarming as post-vaccination vascular events culminate either in severe disability or death. Vaccine-induced cerebral vascular adverse events are generally associated with severe immune-mediated thrombotic thrombocytopenia. Thrombocytopenia generally clinically manifests within 5 to 30 days after administration of adenovirus vector-based vaccines. In post-vaccination thrombotic thrombocytopenia, a picture similar to that of heparin-induced thrombocytopenia is encountered. When heparin binds platelet factor 4, there is generation of antibodies against platelet factor 4. Antibodies against platelet factor 4 result in platelet destruction and trigger the intravascular blood clotting [14]. The post-mortem examination, in patients with vaccine-induced thrombocytopenia, demonstrated extensive involvement of large venous vessels. Microscopic findings showed vascular thrombotic occlusions occurring in the vessels of multiple body organs along with marked inflammatory infiltration [15]. The vector-based vaccines contain genetic material of SARS-COV-2 that is capable of encoding the spike glycoprotein. Possibly, leaked

Fig. 1 A flow diagram depicts the spectrum of severe neurological complications following COVID-19 vaccinations (ADEM, acute disseminated encephalomyelitis; CVST, cerebral venous sinus thrombosis; LETM, longitudinally extensive transverse myelitis; MS, multiple sclerosis; NMOSD, neuromyelitis optica spectrum disorders; PRES, posterior reversible encephalopathy syndrome; TIA, transient ischemic attacks)



genetic material binds to platelet factor 4 that subsequently activates formation of autoantibodies. These autoantibodies destroy platelets [16, 17].

Cerebral venous thrombosis

Cerebral venous thrombosis is the one of the most feared devastating COVID-19 vaccine-associated neurological complication. Cerebral venous thrombosis should be suspected in all vaccinated patients, who has persistent headache. Headache is generally unresponsive to the analgesics, and some patients may have focal neurological deficits. Affected patients are generally females of younger ages (Table 1) [18–46].

In Europe, since March 2021, cases of cerebral venous thrombosis started pouring in following COVID-19 vaccination, particularly after administration of viral vector based (AstraZeneca ChAdOx1 nCoV-19 and the Johnson and Johnson Ad26. COV2.S) vaccines [22]. Scully and colleagues recently reported findings of 23 patients, who presented with thrombosis and thrombocytopenia (platelet counts below $10 \times 10^9/L$). These patients developed thrombosis and thrombocytopenia 6 to 24 days after they received the first dose of the viral vector-based vaccines. In a significant observation, authors, in majority of patients, demonstrated the presence of autoantibodies against platelet factor 4. Additionally, D-dimer levels were found elevated [20]. Tiede and co-workers reported five German cases of prothrombotic immune thrombocytopenia after vaccination with viral vector-based vaccine (Vaxzevria). In these patients, acute vascular events clinically manifested as cerebral venous sinus thrombosis, splanchnic vein thrombosis, arterial cerebral thromboembolism, and/or thrombotic microangiopathy within 2 weeks post vaccination. All five patients had low platelet counts and markedly raised D-dimer. In all, autoantibodies against platelet factor 4 were also demonstrated [30].

Pottegård et al. in Denmark and Norway evaluated incidence of arterial events, venous thromboembolism, thrombocytopenia, and bleeding among vaccinated population. The vaccinated cohorts comprised of 148,792 Danish people and 132,472 persons from Norway. All has received their first dose of viral vector-based vaccine (ChAdOx1-S). An excess rate of venous thromboembolism (like cerebral venous thrombosis) was observed among vaccine recipients, within 28 days of vaccine administration. Authors estimated an increased rate for venous thromboembolism corresponding to 11 excess events per 100,000 vaccinations with 2.5 excess cerebral venous thrombosis events per 100,000 vaccinations [47].

Krzywicka et al., from the Netherlands, collected data of 213 cases with post-vaccination (187 after adenoviral vector vaccines and 26 after a mRNA vaccine) cerebral venous

sinus thrombosis; they noted thrombocytopenia in 107/187 (57%) post-vaccination cerebral venous sinus thrombosis cases. Thrombocytopenia was not recorded in any of patients, who received an mRNA-based vaccine. Cerebral venous sinus thrombosis after adenoviral vector vaccines carried poorer prognosis. Approximately, 38% (44/117) patients in adenoviral vector vaccine group died, while in mRNA vaccine group, 20% (2/10) had died [48].

Recently published National Institute for Health and Care Excellence (NICE) guidelines recommend that the patients with clinical diagnosis of vaccine-induced immune thrombocytopenia and thrombosis should be treated with intravenous administration of human immunoglobulin, at a dose of 1 g/kg. If there is no response or there is further deterioration, second dose of human immunoglobulin should be given. In patients with insufficient response, methylprednisolone 1 g intravenously for 3 days or dexamethasone 20 to 40 mg for 4 days can be used [49].

Heparin needs to be avoided, instead alternative anticoagulants like argatroban, bivalirudin, fondaparinux, rivaroxaban, or apixaban should be used for anticoagulation [49–51]. NICE guidelines further recommend that patients with very low platelet count should be treated either alone with a argatroban or a combination of argatroban and platelet transfusion [49].

Arterial events

Several acute arterial events, like arterial thrombosis, intracerebral hemorrhage, transient global amnesia, and spinal artery ischemia, have also been reported following vaccination [31].

Simpson and colleagues, in Scotland, estimated the incidence of vaccine-associated thrombocytopenia and vascular events following administration of first dose of viral vector-based vaccine (ChAdOx1) or mRNA (BNT162b2 Pfizer-BioNTech or mRNA-1273 Moderna) vaccination. First dose of viral vector-based vaccine was associated with small enhanced risk of idiopathic thrombocytopenic purpura; in addition, up to 27 days after vaccination, there was possibility of an increased risk for thromboembolic and hemorrhagic events. No such adverse associations were noted with mRNA vaccines [52]. The reports of COVID-19 vaccine-related intracerebral hemorrhage and ischemic stroke are summarized in Table 2 [53–61].

Intracerebral hemorrhage

Athyros and Doumas reported a 71-year-old female. who developed intracerebral hemorrhage after she received the first dose of the Moderna mRNA vaccine.

Table 1 Clinical, magnetic resonance imaging findings, and outcome details of patients who developed cerebral venous sinus thrombosis after vaccination against SARS-CoV-2

Reference	Neurological complications	Country	Age/sex	Vaccine type	Duration of onset after vaccination	Clinical features	Neuroimaging	Treatment given
Castelli et al. [18]	Cerebral venous sinus thrombosis	Italy	50/M	COVID-19 vaccine AstraZeneca	10 days	Severe headache, right hemiparesis, unsteady gait, and visual impairment of 4 days Patient needed ICU care and mechanical ventilation	Intra-parenchymal hemorrhage CT angiography = left transverse and sigmoid venous sinuses thrombosis	Fibrinogen concentrate (10 g total) and platelet (4 units total) a bilateral decompressive craniectomy
D'Agostino et al. [19]	Cerebral venous thrombosis and disseminated intravascular coagulation	Italy	54/F	The AstraZeneca vaccine	12 days	Altered sensorium and hemiparesis Myocardial infarction	Multiple subacute lobar hemorrhages basilar artery thrombosis associated with the superior sagittal sinus thrombosis Bilateral adrenal hemorrhage	Intensive care unit
Scully et al. (report of 23 patients) [20]	Thrombocytopenia (23 patients) Cerebral venous thrombosis (13 patients)	London	12 years (Median)	ChAdOx1 nCoV-19 vaccine (AstraZeneca)	6 to 24 days	13 patients with cerebral venous thrombosis	Not available	Not available
Franchini et al. [21]	Cerebral venous thrombosis	Italy	50/M	COVID-19 vaccine AstraZeneca	7 days	Coma thrombocytopenia	Intra-parenchymal hemorrhage Angiography cerebral venous sinus thrombosis	Intensive care unit

Table 1 (continued)

Reference	Neurological complications	Country	Age/sex	Vaccine type	Duration of onset after vaccination	Clinical features	Neuroimaging	Treatment given
Mehta et al. [22]	Cerebral venous sinus thrombosis	UK	32/M	Vaxzevria vaccine	9 days	Thunderclap headache Left hemiparesis, left-sided incoordination Thrombocytopenia and rapidly evolving coma	Superior sagittal sinus and cortical vein thrombosis and significant cortical edema with small areas of parenchymal and subarachnoid hemorrhage	Intensive care unit
Bersinger et al. [23]	Cerebral venous sinus thrombosis	France	25/M	Vaxzevria vaccine	6 days	Headache hemiparesis, left hemisensory loss Seizures, agitation, decerebrate posturing, reduced GCS Thrombocytopenia	Superior sagittal sinus thrombosis with extension into the cortical veins and hemorrhage in lobar and sub-arachnoid locations	Intensive care unit
Ramdeny et al. [24]	Cerebral venous sinus thrombosis	United Kingdom	54/M	COVID-19 Vaccine AstraZeneca	21 days	Worsening headache, bruising and unilateral right calf swelling Thrombocytopenia D-dimer = 60,000 ng/ml Anti-platelet factor 4	CT of the head showed massive thrombosis in the deep and superficial cerebral veins, thrombosis of the left jugular vein, and left frontoparietal venous hemorrhagic infarction Cerebral venous sinus thrombosis	A selective arterial embolization was performed immediately after decompressive craniectomy IV immunoglobulin Fondaparinux Intravenous immunoglobulin

Table 1 (continued)

Reference	Neurological complications	Country	Age/sex	Vaccine type	Duration of onset after vaccination	Clinical features	Neuroimaging	Treatment given
Zakaria et al. [25]	Cerebral venous sinus thrombosis	Malaysia	49/M	First dose of mRNA SARS-CoV-2 vaccine	16 days	New onset of mild to moderate headache and giddiness	CT of the brain showed cordlike hyperattenuation within the left transverse and sigmoid sinus suggestive of cord or dense clot sign CT cerebral venography a long segment-filling defect and empty delta sign within the superior sagittal sinus extending into the torcula Herophili, left transverse sinus, and sigmoid sinus to proximal internal jugular vein	Subcutaneous Clexane improved
Ryan et al. [26]	Cerebral venous sinus thrombosis	Ireland	35/F	AZD1222 (COVID-19 Vaccine AstraZeneca)	10 days	Headache thrombocytopenia bruising and petechiae Antibody to platelet factor 4	MR venogram showed cerebral venous sinus thrombosis	Apixaban
Graf et al. [27]	Cerebral venous sinus thrombosis	Germany	29/M	ChAdOx1 nCoV-19, AstraZeneca	9 days	Severe headache and hematemesia thrombocytopenia	Complete thrombosis of the left transverse and sigmoid sinus down to the left proximal jugular vein Temporo-parietal intracranial hemorrhage CT angiography revealed extensive thrombosis of the mesenteric and portal vein	High-dose immunoglobulins Argatroban

Table 1 (continued)

Reference	Neurological complications	Country	Age/sex	Vaccine type	Duration of onset after vaccination	Clinical features	Neuroimaging	Treatment given
George et al. [28]	Cerebral venous sinus thrombosis	USA	40/F	ChAdOx1 nCoV-19, AstraZeneca	7 days	Headache thrombocytopenia Antibody to platelet factor 4	Venous thrombosis involving the left transverse sigmoid sinus and internal jugular vein	A direct thrombin inhibitor (bivalirudin) Intravenous immune globulin (IVIg)
Jamme et al. [29]	Cerebral venous sinus thrombosis	France	69/F	First dose of Oxford–AstraZeneca vaccine	11 days	Headache associated with behavioral symptoms	Bilateral frontal hemorrhage cerebral venous thrombosis of the left internal jugular vein, sigmoid sinus, and superior sagittal sinus	None
Tiede et al. (report of 5 patients) [30]	Cerebral venous sinus thrombosis	Germany	41 and 67 years All females	ChAdOx1 COVID-19 vaccine (AZD1222, Vaxzevria)	5 to 11 days after first vaccination	Cerebral venous sinus thrombosis (CVST), splanchnic vein thrombosis (SVT), arterial cerebral thromboembolism, and thrombotic microangiopathy thrombocytopenia Autoantibodies against platelet factor 4	Brain hematomas infarcts, presence of thrombi in major vessels	Intravenous immunoglobulin or corticosteroids Argatroban
Schulz et al. (report of 45 cases) [31]	Cerebral venous thrombosis	Germany	46.5 years (mean)/35 females	BNT162b2, ChAdOx1, and mRNA-1273	Within 30 days of vaccination	Thrombocytopenia in all patients	Cerebral venous thrombosis	Intravenous immunoglobulins, plasmapheresis, corticosteroids, anticoagulants

Table 1 (continued)

Reference	Neurological complications	Country	Age/sex	Vaccine type	Duration of onset after vaccination	Clinical features	Neuroimaging	Treatment given
Bourguignon et al. [32]	A report three patients one had cerebral venous sinus thrombosis	Canada	69/M	ChAdOx1 nCoV-19, AstraZeneca	12 days	Diabetes mellitus, hypertension, obstructive sleep apnea, recently diagnosed prostate cancer Headache and confusion left-sided weakness Thrombocytopenia Autoantibodies against platelet factor 4	Right middle cerebral-artery stroke with hemorrhagic transformation Right cerebral transverse and sigmoid sinuses, right internal jugular vein, hepatic vein, and distal lower-limb vein; pulmonary embolism	Intravenous immunoglobulin Plasmapheresis
Gattringer et al. [33]	Cerebral venous sinus thrombosis	Austria	39/F	The first vaccination with ChAdOx1 nCoV-19 (AstraZeneca)	8 days	Headache since 2 days thrombocytopenia ($84 \times 10^9/L$)	Left sigmoid/transverse sinus thrombosis without brain parenchymal involvement	Intravenous immunoglobulin
Ikenberg et al. [34]	Cerebral venous sinus thrombosis	Germany	early 30 s/F	The first dose of ChAdOx1 nCoV-19 (AstraZeneca)		Headache Gait ataxia, and amnesic difficulties as well as aphasia Thrombocytopenia of $37\ 000/\mu L$	CVST of the left transverse and sigmoidal sinus with a left-temporal and left-cerebellar intracerebral hemorrhage	Intravenous immunoglobulin argatroban
Clark et al. [35]	Cerebral venous sinus thrombosis	USA	40/F	The Ad26.COV2.S (Johnson & Johnson/ Jansen) vaccine	5 days	Worsening headaches thrombocytopenia	Cerebral venous sinus thrombosis involving the left transverse and sigmoid sinuses, extending into the left internal jugular vein	Bivalirudin infusion Intravenous immunoglobulin

Table 1 (continued)

Reference	Neurological complications	Country	Age/sex	Vaccine type	Duration of onset after vaccination	Clinical features	Neuroimaging	Treatment given
Bonato et al. [36]	Cerebral venous sinus thrombosis	Italy	26/F	ChAdOx1 nCoV-19 vaccine	14 days	headache non-responsive to drugs right-sided weakness and visual disturbances rapidly deteriorated with decreased consciousness	Multifocal venous thrombosis with bilateral occlusion of parietal cortical veins, straight sinus, vein of Galen, internal cerebral veins, and inferior sagittal sinus. Right parietal and left frontoparietal lobes an extensive venous infarction with hemorrhagic transformation Platelet-factor 4 (PF4)-heparin IgG antibodies – elevated thrombocytopenia	Dexamethasone Intravenous immunoglobulin argatroban
Wang et al. [37]	Cerebral venous sinus thrombosis	Taiwan	41/F	First vaccination with ChAdOx1 nCoV-19	7 days	Fever and headache thrombocytopenia positive anti-PF4 antibodies	MR venography revealed cerebral venous sinus thrombosis	Intravenous immunoglobulin
Dutta et al. [38]	Cerebral venous sinus thrombosis	India	51/M	First-dose of COVISHIELD	6 days	Headache double vision papilledema Platelet count was normal	MR venography revealed thrombosis in superior sagittal sinus and transverse sinus	Low-molecular-weight heparin
Aladdin et al. [39]	Cerebral venous sinus thrombosis	Saudi Arabia	36/F	First dose of the ChAdOx1 nCoV-19 vaccine	14 days	Vomiting and severe headache left upper limb weakness thrombocytopenia Disseminated intravascular coagulation	Brain computed tomography (CT) scan showed superior sagittal thrombosis with thickened cortical veins and bilateral hypodensities in the parietal lobes	Low-molecular-weight heparin ICU care

Table 1 (continued)

Reference	Neurological complications	Country	Age/sex	Vaccine type	Duration of onset after vaccination	Clinical features	Neuroimaging	Treatment given
Lavin et al. (a series of 4 patients) [40]	Cerebral venous sinus thrombosis	Ireland	29/F 38/M 50/F 35/F	Vaxzevria vaccine (ChAdOx1 nCoV-19, Astra-Zeneca)	10 days 16 days 23 days 14 days	Visual disturbance followed by a headache, nausea, vomiting, bruising and petechiae severe thunderclap headache, nausea and vomiting headache, persistent bruising and petechiae all had thrombocytopenia	Dural venous sinus thrombosis in one patient only other had abdominal abnormalities	Intravenous immunoglobulin
Tølbøll Sørensen et al. [41]	Cerebral venous sinus thrombosis	UK	30/F	ChAdOx1 nCoV-19		Headache and general malaise portal vein thrombosis thrombocytopenia and consumption coagulopathy Anti-platelet antibodies were detected	Normal	Tinzaparin
Fan et al. [42] (a series of 3 patients)	Cerebral venous sinus thrombosis	Singapore	54/M 62/F 60/F	BNT162b2 mRNA vaccination	1 day 9 days 8 days	Severe headache and vomiting and acute left hemiparesis Headache and vomiting Right ataxic hemiparesis There was no thrombocytopenia	A large right temporo-parietal lobe intraparenchymal hemorrhage Acute right cerebral bleed involving occipital and temporal lobes associated with subarachnoid hemorrhage Venous infarct in bilateral perirolandic gyri Venogram confirmed cerebral venous sinus thrombosis in all three	Low-molecular-weight heparin decompressive craniectomy

Table 1 (continued)

Reference	Neurological complications	Country	Age/sex	Vaccine type	Duration of onset after vaccination	Clinical features	Neuroimaging	Treatment given
Suresh and Petchey [43]	Cerebral venous sinus thrombosis	UK	27/M	ChAdOx1 nCoV-19 vaccine	2 days	Worsening headache and new homonymous hemianopia. Thrombocytopenia. Anti-platelet antibodies were detected	Acute parenchymal bleed with subdural extension. CT venogram confirmed significant cerebral venous sinus thrombosis	Dabigatran and intravenous immunoglobulins
Dias et al. (a series of 2 patients) [44]	Cerebral venous sinus thrombosis	Portugal	47/F 67/F	BNT162b2 mRNA SARS-CoV-2 vaccine	6 days 3 days	Headache, nausea and photophobia a sudden left motor deficit. Sudden right lower limb clonic movements, followed by motor deficit, loss of consciousness and headache. There was no thrombocytopenia. Anti-platelet antibodies were not detected	MRI with venography revealed thrombosis of superior sagittal, right lateral, transverse, sigmoid sinuses, and jugular vein and left sigmoid sinus, together with right frontal subarachnoid hemorrhage and a cortical venous infarct. Brain MRI showed thrombosis of high convexity cortical veins, superior sagittal, right transverse, and sigmoid sinus and jugular vein	Acetazolamide and enoxaparin. Lev- etiracetam 500 mg bid and enoxaparin

Table 1 (continued)

Reference	Neurological complications	Country	Age/sex	Vaccine type	Duration of onset after vaccination	Clinical features	Neuroimaging	Treatment given
Guan et al. [45]	Cerebral venous sinus thrombosis	Taiwan	52/M	The first dose of ChAdOx1 nCoV-19 (AstraZeneca)	10 days	Nausea and thunderclap headache thrombocytopenia Platelet factor 4 antibodies detected	Hyperdensity of the sinus, including cord sign and dense vein sign at the left transverse and sigmoid sinuses CT venogram revealed CVST at the left transverse sinus and sigmoid sinuses and thrombosis of the left internal jugular vein	Apixaban Outcome not provided
Varona et al. [46]	Cerebral venous sinus thrombosis and primary adrenal insufficiency	Spain	47/M	Adenoviral (ChAdOx1) vector-based COVID-19 vaccine	10 days	Headache, somnolence, and mild confusion Bilateral segmentary pulmonary embolism Thrombocytopenia Anti-platelet antibodies were detected	Consistent with cerebral venous thrombosis	Intravenous immunoglobulins and subcutaneous fondaparinux hydrocortisone Patient improved

Table 2 Clinical, neuroimaging and outcome details of patients who suffered strokes (other than cerebral venous thrombosis) after vaccination against SARS-CoV-2

Reference	Neurological complication	Country	Age/sex	Vaccine type	Duration after vaccination	Clinical features	Neuroimaging	Treatment	Outcome
Athyros and Doumas [53]	Intracerebral hemorrhage	Greece	71/F	Moderna anti-COVID-19 vaccine	3 days	Right hemiplegia, aphasia, agnosia Acute hypertensive crisis	Left basal ganglia hemorrhage	Clonidine, furosemide	Died
Bjørnstad-Tuveng [54]	Intracerebral hemorrhage	Norway	Thirties/F	AstraZeneca's vaccine ChAdOx1 nCoV-19	9 days	Slurred speech, left hemiparesis, and reduced consciousness	Right intracerebral hemorrhage on CT, thrombosis in transverse sinus and pulmonary artery on postmortem	ICU management	Died
de Mélo Silva et al. [55]	Intracerebral hemorrhage with intraventricular extension	Brazil	57/F	ChAdOx1 nCoV-19 vaccine	5 days	Left hemiparesis, vomiting, and somnolence	A large right deep frontal lobe parenchymal hematoma	ICU management Decompressive craniectomy	Survived with disabilities
Bayas et al. [56]	Bilateral superior ophthalmic vein thrombosis, ischemic stroke, and immune thrombocytopenia	Germany	55/F	SARS-CoV-2— ChAdOx1 nCoV-19	10 days	Flu-like illness, diplopia, vision loss, a transient, mild, right-sided hemiparesis, and aphasia, focal seizures	MRI showed superior ophthalmic vein thrombosis An MRI showed an ischemic stroke in the left parietal lobe, middle cerebral artery territory, with restricted diffusion	Intravenous dexamethasone Anticoagulants	Improved
Al-Mayhani et al. [57]	Ischemic stroke with thrombocytopenia	London	35/F 37/F 43/F	ChAdOx1 nCoV-19 vaccine ChAdOx1 nCoV-19 vaccine ChAdOx1 nCoV-19 vaccine	11 days 12 days 21 days	Left face, arm, leg weakness and drowsiness Headache, left visual field loss, confusion, left arm weakness Dysphasia	Right middle-cerebral artery infarct Bilateral acute border zone infarcts Left middle-cerebral artery infarct	Decompressive hemi-craniectomy Intravenous immunoglobulin Intravenous immunoglobulin	Died Improved Stable

Table 2 (continued)

Reference	Neurological complication	Country	Age/sex	Vaccine type	Duration after vaccination	Clinical features	Neuroimaging	Treatment	Outcome
Blauenfeldt et al. [58]	Ischemic stroke	Denmark	60/M	mRNA-based vaccine BNT162b2 (Pfizer/BIO-TECH)	7 days	Bilateral adrenal hemorrhages A massive right sided ischemic stroke Thrombocytopenia Platelet factor 4 (PF-4) reactive antibodies	Angiography showed occlusion of the right internal. Carotid artery	Intensive care unit	Palliative care
Malik et al. [59]	transient ischemic attack	USA	43/F	Johnson and Johnson COVID-19 Ad26.COV2.S vaccination	10 days	Headache, fever, body aches, chills, mild dyspnea and light-headedness thrombocytopenia numbness and tingling of her face and right arm	Right internal carotid artery (ICA) thrombus	Fondaparinux	Improved
Finsterer and Korn [60]	Aphasia	Austria	52/M	The second dose of an mRNA-based SARS-CoV-2 vaccine	7 days	Sudden-onset reading difficulty and aphasia motor aphasia with paraphasia	A lobar bleeding in the left temporal lobe	Supportive	Improved
Walter et al. [61]	Ischemic stroke Main stem occlusion of middle cerebral artery	Germany		First dose ChAdOx1 nCoV-19 vaccine		acute headache, aphasia, and hemiparesis Platelet count and fibrinogen level were normal	Main stem occlusion of middle cerebral artery A wall-adherent, non-occluding thrombus in the ipsilateral carotid bulb was noted	Within 1 h after start of IV thrombolysis	Thrombus dissolved and patient improved

On the third post-vaccination day, the patient developed right hemiplegia, aphasia, and agnosia along with accelerated hypertension. Computed tomography revealed a hematoma in the left basal ganglia. On the 9th day, she died [53].

In another report, Bjørnstad-Tuveng et al. described a young woman, who had a fatal cerebral event following vaccination with AstraZeneca's ChAdOx1 nCoV-19 vaccine. She was found to have severe thrombocytopenia. The patient died the next day of the event. Post-mortem examination revealed antibodies against platelet factor 4 and the presence of small thrombi in the transverse sinus, frontal lobe, and pulmonary artery [54].

Acute ischemic stroke

Bayas and co-workers described a case that presented with superior ophthalmic vein thrombosis, ischemic stroke, and immune thrombocytopenia, after administration of viral vector-based vaccine. Intravenous dexamethasone resulted in marked improvement in platelet count [56]. Al-Mayhany et al. described three cases of vaccine-induced thrombotic thrombocytopenia, all presented with arterial strokes. Authors opined that young patients with arterial stroke after receiving the COVID-19 vaccine should always be evaluated for vaccine-induced thrombotic thrombocytopenia. Other laboratory tests, like platelet count, D-dimers, fibrinogen level, and testing for platelet factor 4 antibodies, should also be performed [57].

Blauenfeldt et al. described a 60-year-old woman, who presented with intractable abdominal pain, 7 days after receiving the adenoviral (ChAdOx1) vector-based COVID-19 vaccine. Abdominal computed tomography revealed bilateral adrenal necrosis. Later, a massive right cerebral infarction, secondary to occlusion of the right internal carotid artery, occurred that led to death of the patient. Blood tests showed thrombocytopenia, elevated in D-dimer and platelet factor 4 antibodies [58].

Many reports of acute brain disorders like encephalopathy, seizures, acute disseminated encephalopathy, neuroleptic malignant syndrome, and post-vaccine encephalitis were described secondary to COVID-19 vaccine. These are summarized in Table 3 [62–75].

Encephalopathy

Some patients developed encephalopathy following administration of COVID-19 vaccines. Acute encephalopathy is defined as rapidly evolving disorder of the brain. Acute encephalopathy clinically manifests either with delirium, decreased consciousness, or coma.

Delirium

Delirium is characterized with fluctuating disturbance in attention and awareness. Zavala-Jongitud and Pérez-García described an 89-year-old man, who developed delirium after mRNA vaccination. Within 24 h, patient developed confusion, fluctuating attention, anxiety, and inversion of the sleep–wake cycle. Patient had many comorbidities (diabetes mellitus, hypertension, and chronic kidney disease). Patient improved after he was treated with quetiapine [68].

Neuroleptic malignant syndrome

Neuroleptic malignant syndrome is a life-threatening complication of many antipsychotic drugs characterized by fever, altered mental status, muscle rigidity, and autonomic dysfunction. In an isolated report, neuroleptic malignant syndrome, in a 74-year-old female with dementia and bipolar disorder 16 days after COVID-19 vaccination, has been described [69].

Acute disseminated encephalomyelitis

Acute disseminated encephalomyelitis (ADEM) is an acute inflammatory demyelinating disorder of the central nervous system. In the majority, ADEM is a post-infectious entity; in many cases, it even develops after vaccination [76]. In two cases, acute disseminated encephalomyelitis following COVID-19 vaccination has been reported. In first such case a 46-year-old woman received Sinovac inactivated SARS-CoV-2 vaccine before onset of clinical manifestations. Patient was presented with seizures, and magnetic resonance imaging revealed multiple, discrete T2/FLAIR periventricular hyperintense lesions. Patient improved following methylprednisolone treatment [70]. Another patient was a 24-year-old female who presented with encephalopathy along with limb weakness of 1-day duration. Two weeks prior, patient was vaccinated with inactivated SARS-CoV-2 vaccine. Magnetic resonance imaging revealed multiple, discrete T2/FLAIR hyperintense lesions in the brain. Patient improved following treatment with antiepileptics and intravenous immunoglobulins [71].

Post-vaccinal encephalitis

Zuhorn et al. reported a case series 3 patients, who presented with post-vaccinal encephalitis, akin to autoimmune encephalitis, 7 to 11 days after administration of adenovirus-based ChAdOx1 nCov-19 vaccine. All patients fulfilled the diagnostic criteria for possible autoimmune encephalitis. One interesting case had presented with opsoclonus-myoclonus syndrome. Two patients presented with cognitive decline, seizures, and gait disorder.

Table 3 Clinical, neuroimaging and outcome details of patients who presented with an acute brain disorder (other than cerebral venous thrombosis and arterial stroke) after vaccination against SARS-CoV-2

Reference	Neurological complication	Country	Age/sex	Vaccine type	Duration after vaccination	Clinical features	Neuroimaging	Treatment	Outcome
Baldelli et al. [62]	Reversible encephalopathy	Italy	77/M	The first dose of ChAdOx1 nCoV-19 vaccine (AstraZeneca)	1 day	Delirium A significant increase of interleukin (IL)-6 in both CSF and serum	Normal	Corticosteroids	
Aladdin and Shiraith [63]	New-onset refractory status epilepticus	Saudi Arabia	42/F	ChAdOx1 nCoV-19 vaccine	10 days	Headache and fever first-ever generalized tonic-clonic seizure lorazepam, levetiracetam, and phenytoin failed to control	Increase in the signal on FLAIR images at bilateral hippocampi and insula	Midazolam and propofol Plasma exchange	Improved
Ghosh et al. [64]	Seizures	India	68/M	Covishield vaccine	4 days	Focal onset non-motor seizure	Periventricular leukoariosis and cortical atrophy	brivaracetam	Improved
Liu et al. [65] (two cases)	Associated with non-convulsive status epilepticus	USA	86/F 73/M	Moderna COVID-19 vaccine	7 days 21 days	Diastolic dysfunction, chronic kidney disease and diabetes mellitus with acute encephalopathy Acute confusion with visual hallucinations EEG demonstrated non-convulsive focal status epilepticus Acute encephalopathy with non-convulsive status epilepticus	Normal	Antiepileptic therapy and ICU care	Both improved
Naharci and Tasc [66]	Delirium	Turkey	88/F	first dose of CoronaVac--an inactivated COVID-19 vaccine		Acute confusion, hallucinations, agitation, and sleep disturbance	None	Haloperidol and trazodone	Improved

Table 3 (continued)

Reference	Neurological complication	Country	Age/sex	Vaccine type	Duration after vaccination	Clinical features	Neuroimaging	Treatment	Outcome
Salinas et al. [67]	Transient akathisia	USA	36/F	Pfizer-BioNTech vaccine	Within 24 h of second dose	Restless body syndrome had fever after 5 h of motor restlessness resolved after 24 h	None	None	Improved
Zavala-Jonguitud et al. [68]	Delirium	Mexico	89/M	The first dose of BNT162b2 RNA vaccine	24 h	Acute confusion, fluctuating attention, anxiety and inversion of the sleep–wake cycle History of type 2 diabetes mellitus, hypertension, stage III-b chronic kidney disease, prostatic hyperplasia	Not done	Quetiapine	Improved
Alfshawy et al. [69]	Neuroleptic malignant syndrome	Kuwait	74/F	BNT162b2 mRNA COVID-19 vaccine	16 days	Old case of dementia and bipolar disorder and was receiving memantine, donepezil, and quetiapine presented with fever, delirium, rigidity, and elevated CPK	Normal	Symptomatic	Improved
Ozen Kengngil et al. [70]	Acute disseminated encephalomyelitis like MRI lesions	Turkey	46/F	Inactivated SARS-CoV-2 vaccine of Sinovac	1 Month	Seizures, normal examination	T2, FLAIR hyperintensity in thalamus, and corona radiata	Methyl prednisolone	No recurrence of seizures
Cao and Ren [71]	Acute disseminated encephalomyelitis	China	24/F	SARS-CoV-2 Vaccine (Vero Cell), Inactivated	2 weeks	Somnolence and memory decline, MMSE-11 inflammatory changes in CSF	T2/FLAIR white matter hyperintensity in both temporal lobes	IV immunoglobulin	Improved

Table 3 (continued)

Reference	Neurological complication	Country	Age/sex	Vaccine type	Duration after vaccination	Clinical features	Neuroimaging	Treatment	Outcome
Raknuzzaman et al. [72]	Acute disseminated encephalomyelitis	Bangladesh	55/M	BNT162b2 mRNA COVID-19 vaccine	3 weeks	Delirium followed by loss of consciousness	T2/FLAIR white matter hyperintensities in periventricular region	Methylprednisolone	Improved
Torrealba-Acosta et al. [73]	Acute encephalitis, myoclonus and Sweet syndrome	USA	77/M	mRNA-1273 vaccine	1 day	Confusion, fever and generalized rash; later headache, dizziness and double vision leading to severe encephalopathy. Intermittent orofacial movements and upper extremity myoclonus. CSF showed increased cells and protein. Skin biopsy showed vasculitis changes	Normal	Methylprednisolone	Improved
Vogrig et al. [74]	Acute disseminated encephalomyelitis	Italy	56/F	Pfizer-BioNTech COVID-19 vaccine (Comirnaty)	2 weeks	Horizontal gaze-evoked nystagmus, Mild weakness on left upper limb, left hemi-ataxic gait	T2/FLAIR white matter hyperintensity in left cerebellar peduncle. Prednisone improved FLAIR sequences were observed, the largest in the left centrum semiovale	Prednisone	Improved

Table 3 (continued)

Reference	Neurological complication	Country	Age/sex	Vaccine type	Duration after vaccination	Clinical features	Neuroimaging	Treatment	Outcome
Zuhorn et al. [75]	Postvaccinal encephalitis Similar to autoimmune encephalitis	Germany	21/F	ChAdOx1 nCov-19 vaccine the first dose	5 days	Headache and progressive neurological symptoms including attention and concentration difficulties and a seizure CSF lymphocytic pleocytosis EEG slow delta rhythm	Normal	Prednisone	Improved
			63/F	ChAdOx1 nCov-19 vaccine	6 days	Gait disorder, a vigilance disorder and a twitching all over her body Opoclonus-myoclonus syndrome CSF lymphocytic pleocytosis EEG slow delta rhythm	Normal	Methylprednisolone	Improved
			63/M	ChAdOx1 nCov-19 vaccine	8 days	Isolated aphasia and fever CSF lymphocytic pleocytosis EEG normal	Normal	None	Mild improvement despite no treatment

Neuroimaging did not reveal any abnormality. CSF pleocytosis was noted in all three patients. All patients responded well to corticosteroids [75].

Transverse myelitis

Acute transverse myelitis is an inflammatory spinal cord disorder that clinically manifests with the paraparesis/quadruparesis, transverse sensory level, and bowel or bladder dysfunction. Acute transverse myelitis usually is a postinfectious disorder. Magnetic resonance imaging demonstrates T2/FLAIR hyperintensity extending several spinal cord segments. Autoimmunity via mechanism of molecular mimicry is usually responsible for spinal cord dysfunction. Adenoviral vector-based COVID-19 vaccines are more frequently associated with causation of transverse myelitis. In isolated cases, even inactivated virus vaccine and mRNA-based vaccines had precipitated acute demyelination spinal cord syndromes, like multiple sclerosis and neuromyelitis optica. Reports of myelitis associated with vaccination for SARS-CoV-2 are summarized in Table 4 [77–83].

Malhotra and colleagues reported a 36-year-old patient, who had short-segment myelitis 21 days after first dose of adenoviral vector-based (Oxford/AstraZeneca, COVISHIELD™) vaccine. Patient recovered completely after treatment with methylprednisolone [77]. Fitzsimmons and Nance reported another patient of acute transverse myelitis following Moderna vaccine (an mRNA vaccine). The 63-year-old patient developed symptoms of acute myelopathy within 24 h of vaccination. MRI revealed increased T2 cord signal seen in the distal spinal cord and conus. Patient improved considerably following treatment with methylprednisolone and intravenous immunoglobulin [78].

Earlier, in phase III trial of Oxford/AstraZeneca vaccine, 2 patients had developed transverse myelitis. One of the case of transverse myelitis was reported 14 days after booster vaccination. The expert committee considered that this case was the most likely an idiopathic, short segment transverse myelitis. The second case was reported 68 days post-vaccination. Experts believed that in this case, transverse myelitis was not likely to be associated with vaccination. This patient was earlier diagnosed as a case of multiple sclerosis [84, 85].

The pathogenesis of acute transverse myelitis following COVID-19 vaccination remains unknown. Possibly, SARS-CoV-2 antigens present in the COVID-19 vaccine or its adenovirus adjuvant induce immunological reaction in the spinal cord. The occurrence of 3 reported acute transverse myelitis adverse effects among 11,636 participants in the vaccine trials was considered high and a cause of concern [86].

Bell's palsy

Several cases of Bell's palsy have occurred following COVID-19 vaccination. (Table 5) [87–95]. The instances of Bell's palsy are most often associated with mRNA vaccines [96]. Vaccine-associated Bell's palsy generally responds very well to the oral corticosteroids. The exact pathogenesis remains speculative.

In a case–control study, Shemer et al. compared clinical parameters of patients with Bell's palsy following mRNA vaccination with that of patients with Bell's palsy without vaccination. Out of 37 patients, 21 had received vaccination. Bell's palsy developed within 2 weeks following first dose of COVID-19 vaccination. There was no difference in any of the clinical parameter between vaccinated or unvaccinated groups [97].

Earlier, in the Pfizer-BioNTech clinical trial, which included 44,000 participants, 4 people had Bell's palsy. No case of Bell's palsy was reported in the placebo arm. In the Moderna trial, which included 30,400 participants, 3 vaccine recipients reported Bell's palsy. One person was in the placebo arm [98]. An article, published in the *Lancet*, analyzed the combined phase 3 data of Pfizer and Moderna trials and noted that the rate of Bell's palsy was higher than expected [98].

Other cranial nerve involvement

In isolated instances, mRNA vaccines were found associated with olfactory dysfunction and sixth cranial nerve palsy (Table 6) [99–104].

Olfactory dysfunction

Olfactory dysfunction is the most frequent neurological complication of COVID-19. Konstantinidis and colleagues reported two cases of smell impairment after second dose of the BioNTechBNT162b2 vaccine (Pfizer) administration [51].

Keir and colleagues reported phantosmia following administration of Pfizer COVID-19 vaccine. Patient complained of constantly “smelling smoke” and headaches. MRI of brain of the patient showed enhancement of the olfactory bulbs and bilateral olfactory tracts [100].

Abducens nerve palsy

Reyes-Capo et al. reported a 59-year-old lady, who presented with an abducens nerve palsy 2 days post-vaccination

Table 4 Clinical, neuroimaging, and outcome details of patients who presented with spinal cord involvement after vaccination against SARS-CoV-2

Reference	Neurological complication	Country	Age/sex	Vaccine type	Duration after vaccination	Clinical features	Neuroimaging	Treatment	Outcome
Malhotra et al. [77]	Transverse myelitis	India	36/M	Viral-vectored, recombinant ChAdOX1 nCoV-19 Covishield vaccine (AstraZeneca vaccine by Serum Institute of India)	On the 8th post-vaccination day	Abnormal sensations in lower limbs with truncal level	T2-hyperintense lesion in the dorsal aspect of spinal cord at C6 and C7 vertebral levels	Methylprednisolone	Improved
Fitzsimmons and Nance [78]	Transverse myelitis	USA	63/M	Second dose of the Moderna vaccine	Within 1 day	Lower back pain, paresthesia in both feet, and pain in lower extremities difficulty in walking and urinary retention	Increased T2 cord signal seen in the distal spinal cord and conus	Intravenous immunoglobulin and methylprednisolone	Improved
Tahir et al. [79]	Transverse myelitis	USA	44/F	Ad26.COV2.S (Johnson & Johnson) vaccine	10 days	Cervical cord transverse myelopathy CSF increased cells	Increased T2 cord signal seen in the spinal cord extending from the C2-3 segment into the upper thoracic region	Plasma exchange and methylprednisolone	Improved
Pagenkopf and Südmeyer [80]	Longitudinally extensive transverse myelitis	Germany	45/M	First dose COVID-19-vaccine (AZD1222, AstraZeneca)	11 days	Thoracic back pain and urinary retention	T2 hyperintense signal of the spinal cord with wide axial and longitudinal extent reaching from C3 to Th2	Prednisolone	Improved
Helmchen et al. [81]	Optic neuritis with longitudinal extensive transverse myelitis in stable multiple sclerosis	Germany	40/F	Astra Zeneca, COVID19 Vaccine®; Vaxzevria	2 weeks	Blindness paraplegia, with absent tendon reflexes in the legs, incontinence, and a sensory deficit for all qualities below Th5. CSF showed severe pleocytosis and elevated protein	Increased longitudinal centrally located signal intensities throughout the thoracic spinal cord	Corticosteroids and plasmapheresis	Improved

Table 4 (continued)

Reference	Neurological complication	Country	Age/sex	Vaccine type	Duration after vaccination	Clinical features	Neuroimaging	Treatment	Outcome
Havla et al. [82]	First manifestation of multiple sclerosis	Germany	28/F	Pfizer-BioNTech COVID-19 vaccine	6 days first dose	Myelitis oligoclonal bands	MRI revealed multiple (> 20), partially confluent lesions with spatial dissemination but no gadolinium enhancement. Contrast-enhancing lesion at the T6 level, suggestive of myelitis	Methylprednisolone and plasma exchange	Improved
Chen et al. [83]	Neuromyelitis optica spectrum disorder	China	Middle-aged female	The first dose of inactivated virus vaccine	3 days	Dizziness and unsteady walking AQP4-positive	MRI scanning of the brain revealed area postrema and bilateral hypothalamus lesions	Methylprednisolone	Improved

(Pfizer-BioNTech mRNA vaccine). Neuroimaging in this patient was normal..

Otologic manifestations

A variety of otologic manifestations has been noted following COVID-19 vaccination. Parrino and colleagues described three patients with sudden unilateral tinnitus following BNT162b2 mRNA vaccine administration. Tinnitus rapidly resolved in 2 cases. Wichova and colleagues in a retrospective review recorded 30 patients, who either had significantly exacerbated otologic symptoms or had a new symptom after getting mRNA vaccine. Post-vaccination otologic manifestations included hearing loss with tinnitus, dizziness, or with vertigo. In some patients, with Menière's disease or autoimmune inner ear disease, vaccine led to exacerbation of the pre-existing otologic symptoms [102,105].

Acute vision loss

Santovito and Pinna reported an unusual patient, who developed acute visual impairment following the 2nd dose of the Pfizer-BioNTech COVID-19 vaccine. Prior to visual symptoms, patient experienced unilateral headache. He also reported mild confusion, asthenia, and profound nausea. His symptoms got relieved after taking analgesics. Possibly, patient had an acute attack of migraine with aura that got precipitated by the vaccine [106].

Guillain-Barré syndrome

Guillain-Barré syndrome is a post-infectious disorder of peripheral nerve manifesting with lower motor neuron type of sensory-motor quadriparesis. Acute motor weakness is frequently preceded by an antecedent microbial infection. There are numerous reports indicating that COVID-19 infection can trigger Guillain-Barré syndrome. The US Food and Drug Administration has recently expressed its concern regarding a possible association between the Johnson and Johnson COVID-19 vaccine with Guillain-Barré syndrome [107].

After emergency use approvals, all kinds of COVID-19 vaccines were found associated with Guillain-Barré syndrome. Adenovector-based vaccines were more frequently associated with Guillain-Barré syndrome. Earlier, in phase 3 trial of Johnson and Johnson adenovirus vector-based COVID-19 vaccine, 2 patients developed Guillain-Barré syndrome. One patient belonged to vaccine group and other to placebo group. Both patients had Guillain-Barré syndrome within 2 weeks of receiving injections. The Guillain-Barré syndrome in the vaccine arm was preceded by chills, nausea, diarrhea, and myalgia [108, 109].

Table 5 Summary of reported patients, who suffered from Bell's palsy after vaccination against SARS-CoV-2

Reference	Neurological complication	Country	Age/sex	Vaccine type	Duration after vaccination	Clinical features	Neuroimaging	Treatment	Outcome
Shemer et al. (a report of 9 cases) [87]	Bell's palsy	Israel	35–86 (M=5 and F=4)	BNT162b2 SARS-CoV-2 vaccine	4–30 days after first dose 3 received 2nd dose	Acute facial weakness One had herpes zoster ophthalmicus and herpes zoster oticus	None	Corticosteroids	Not given
Repajic et al. [88]	Bell's palsy	USA	57/F	Pfizer-BioNTech COVID-19 A messenger RNA (mRNA) vaccine	36 h after second dose	3 previous episodes of Bell's palsy ageusia Facial weakness	None	Prednisone	Improved
Colella et al. [89]	Bell's palsy	Italy	37/M	mRNA vaccine BNT162b2	5 days after first dose	Acute facial weakness	Not done	Corticosteroids	Improved
Martin-Villares et al. [90]	Bell's palsy	Spain	34/F	Moderna COVID-19 vaccine	2 days	Grade III facial palsy She developed a right Bell's palsy in 2012 during pregnancy (5th month)	None	Corticosteroids	Improved
Nishizawa et al. [91]	Bell's palsy	Japan	62/F	Az26.COVS.S vaccination	20 days	House-Brackmann score 4 Bell's Palsy	Normal	None	None
Gómez de Terreros et al. [92]	Bell's palsy	Spain	50/M	Pfizer-BNT162b2 mRNA vaccine	9 days	Muscle weakness on the left side of his face	Normal	Corticosteroids	Improved
Burrows et al. [93]	Sequential contralateral facial nerve palsies	UK		First and second doses of the Pfizer-BioNTech COVID-19 vaccine	Right palsy, 5 h Left palsy after 2 days	Two discrete contralateral episodes of Bell's palsy	Normal	Prednisolone	Improved both the time
Obermann et al. [94]	Bell's palsy	Germany	21/F	First dose of SARS-CoV-2 mRNA vaccine Comirnaty (BNT162b2, BioNTech/Pfizer)	2 day	Facial muscle paralysis SARS-CoV-2 antibodies were present in blood and CSF	Normal	Prednisolone	Improved
Ifrikhar et al. [95]	Bell's palsy	Qatar	36/M	Second dose of the mRNA-1273 vaccine	1 day	Facial palsy	Normal	Prednisolone	Improved

Table 6 Summary of reported patients, who suffered from cranial nerve involvement (other than Bell's palsy) after vaccination against SARS-CoV-2

Reference	Neurological complication	Country	Age/sex	Vaccine type	Duration after vaccination	Clinical features	Neuroimaging	Treatment	Outcome
Konstantinidis et al. [99] Report of 2 patients	Olfactory dysfunction	Greece	Both female	Pfizer-BioNTech BNT162b2	3 and 5 days after second dose	Hyposmia after their second dose	None	Olfactory training	Improved
Keir et al. [100]	Phantomsmia	USA	57/F	Pfizer-BioNTech COVID-19 vaccination Second dose	None	Feeling weak, fatigued, with random episodes of "smelling smoke" associated with hyposmia	Postcontrast CT demonstrates faint enhancement left olfactory tract MRI enhancement of the left greater than right olfactory bulb and bilateral olfactory tracts	None	None
Reyes-Capo et al. [101]	Acute abducens nerve palsy	USA	59/F	Pfizer-BioNTech COVID-19 vaccine	2 days	Fever for 1 day followed by diplopia	Normal MRI of brain and orbits	Not available	Sensory-motor examination unchanged in recent follow-up
Parrino et al. [102]	Tinnitus	Italy	37/F 63/ 30/M	BNT162b2 mRNA-vaccine	7-h first dose 20 h 7 days	Sudden unilateral tinnitus	Normal MRI	Corticosteroids, in two	Improved all
Tseng et al. [103] PMID: 34,297,133	Reversible tinnitus and cochleopathy	Taiwan	32/M	First dosage of the AstraZeneca COVID-19 vaccine	5 h	High-pitch tinnitus and disturbed the normal hearing high fever with chills and myalgia	Not done	Corticosteroids	Improved
Narasimhalu et al. [104]	Trigeminal and cervical radiculitis	Singapore	52/F	Pfizer-BioNTech vaccination (tozinameran)	3 h first dose	Numbness, swelling and pain over the left face and neck	MRI of trigeminal nerve revealed thickening and perineural sheath enhancement of the V3 segment of the left trigeminal nerve The MRI of the cervical spine revealed spondylotic changes	Pregabalin	Improved

Table 7 Summary of reported patients, who developed an acute peripheral nerve disorder after vaccination against SARS-CoV-2

Reference	Neurological complication	Country	Age/sex	Vaccine type	Duration after vaccination	Clinical features	Neuroimaging	Treatment	Outcome
Wáheed et al. [110]	Guillain-Barré syndrome	USA	82/F	Pfizer-BioNTech COVID-19 A messenger RNA (mRNA) vaccine	2 weeks	Areflexic paraparesis with distal sensory loss CSF showed albuminocytologic dissociation	enhancement of cauda equina nerve roots	IV immunoglobulin	Improved
Márquez Loza et al. [111]	Guillain-Barré syndrome	USA	60/F	Johnson & Johnson, d26, COV2.S, a recombinant adenovirus serotype 26 (Ad26) vector vaccine	2 weeks	Ophthalmoplegia, facial diplegia and Areflexic quadriparesis CSF showed albuminocytologic dissociation	Enhancement of cauda equina nerve roots	IV immunoglobulin	Improved
Patel et al. [112]	Guillain-Barré syndrome	UK	37/M	COVID-19 ChAdOx1 vaccine adenovirus-vectored vaccine Oxford AstraZeneca	2 weeks	Symmetrical, progressive ascending muscle weakness areflexic bilaterally in the lower limbs	Cauda equina nerve root enhancement	Intravenous immunoglobulin	Improved
Razok et al. [113]	Guillain-Barré syndrome	Qatar	73/M	Pfizer-BioNTech COVID-19 vaccine	20 days Second dose	Acute bilateral lower limb weakness	None	IVIg	Improved
Ogbebor et al. [114]	Guillain-Barré syndrome	US	86/3F	Pfizer-BioNTech COVID-19 vaccine	1 day	Weakness in her bilateral lower extremities and by day 6, she could no longer walk CSF = a protein 162 mg/dL and glucose (49 mg/dL)	None	Intravenous immunoglobulin	Improved
Finsterer [115]	Exacerbating Guillain-Barré syndrome	Austria	32/M	A vector-based COVID-19 vaccine	8 days	Paresthesia and dysphagia bilateral frontal and nuchal headache	None	Intravenous immunoglobulin	Improved

Table 7 (continued)

Reference	Neurological complication	Country	Age/sex	Vaccine type	Duration after vaccination	Clinical features	Neuroimaging	Treatment	Outcome
Marammatom et al. [116] Report of 7 cases	Guillain-Barré syndrome	India		ChAdOx1-S/nCoV-19 adenovector-based vaccine	Within 2 weeks of the first dose	All patients progressed to areflexic quadriplegia 2 cases required mechanical ventilation All 7 cases had bilateral facial paresis Four patients (57%) also developed other cranial neuropathies (4th and 5th)	In two patients, MRI brain and spine were normal	Intravenous immunoglobulin	One recovered Rest six still bed bound
Allen et al. [117] Report of 4 cases	Guillain-Barré syndrome variant	UK	20–57 all males	Oxford-AstraZeneca SARS-CoV2 vaccine	Within 3 weeks	Facial weakness in 1 facial diplegia in 3 areflexic quadriplegia in 1 Cyto-albumin dissociation in all	MRI of the brain and whole spine with contrast showed enhancement of the facial nerve within the right internal auditory canal	Intravenous immunoglobulin, oral steroids, or no treatment	All improved
Kohli et al. [118]	Guillain-Barré syndrome	India	71/M	Covishield, AstraZeneca, University of Oxford	6 days	Areflexic quadriplegia with bulbar palsy NCV- demyelinating pattern	None	Intravenous immunoglobulin and mechanical ventilation	Improved
Azam et al. [119]	Guillain-Barré syndrome	UK	67/M	The first dose of the AstraZeneca COVID-19	15 days	Areflexic quadriplegia with facial diplegia NCV- demyelinating pattern	Normal	Intravenous immunoglobulin	Improved

Table 7 (continued)

Reference	Neurological complication	Country	Age/sex	Vaccine type	Duration after vaccination	Clinical features	Neuroimaging	Treatment	Outcome
Hasan et al. [120]	Guillain-Barré syndrome	UK	62/F	First dose of the Oxford/Astra-Zeneca COVID-19 vaccine		Weakness of bilateral lower limbs preceded by paresthesia and numbness and a flaccid-type paraplegia NCV- demyelinating pattern CSF-albumin-cytological dissociation	Normal	Intravenous immunoglobulin	The patient remains in the ICU
Theuriet et al. [121]	Guillain-Barré syndrome	France	72/M	First dose of ChAdOx1 nCoV-19 vaccine (VaxZevria/Oxford-Astra-Zeneca)	3 weeks	Areflexic quadriplegia with facial diplegia NCV- demyelinating pattern	None	Intravenous immunoglobulin	The patient remains in the ICU
Bonifacio et al. [122] (A series of 5 cases)	Guillain-Barré syndrome	UK	43/M 51 M 53/M 66/m 71/f	Vaxzevria AstraZeneca, University of Oxford COVID-19 vaccine	11 days 7 days 7 days 8 days 12 days	Bilateral facial weakness with paresthesia variant of Guillain-Barré syndrome NCV- demyelinating pattern in 4 patients	Bilateral contrast enhancement along whole facial nerve in 3 patients	Intravenous immunoglobulin Was given in 2 patients	All improved
Nasulli et al. [123]	Guillain-Barré syndrome	Italy	59/M	ChAdOx1 nCoV-19 vaccine	10 days	Areflexic quadriplegia with facial diplegia NCV- demyelinating pattern in 4 patients CSF-albumin-cytological dissociation	Normal	Intravenous immunoglobulin	Improved
Jain et al. [124]	Guillain-Barré syndrome	USA	65/F	Ad26.COV2.S (Johnson & Johnson) vaccine	19 days	Facial diplegia	Normal	Intravenous immunoglobulin And plasma-pheresis	Improved

Table 7 (continued)

Reference	Neurological complication	Country	Age/sex	Vaccine type	Duration after vaccination	Clinical features	Neuroimaging	Treatment	Outcome
McKean and Chircop [125]	Guillain-Barré syndrome	Malta	48/M	Vaxzevria AstraZeneca, University of Oxford COVID-19 vaccine First dose	10 days	Facial diplegia and severe back pain ascending paresthesia and bilateral progressive areflexic lower limb weakness. CSF-albumin-cytological dissociation NCV multifocal sensorimotor demyelinating polyneuropathy	Normal	Intravenous immunoglobulin and oral prednisolone	Improved
Bonifacio et al. [126] (a report of 5 cases)	Guillain-Barré syndrome	UK							
Waheed et al. [127]	Small fiber neuropathy	USA	57/F	Pfizer-BioNTech COVID-19 A messenger RNA (mRNA) vaccine (Second dose)	Subacute onset	Intense burning dysesthesias in the feet gradually spreading to the calves and minimally into the hands (Nerve biopsy proved small fiber neuropathy)	None	Gabapentin	Symptomatic improvement

Table 8 Summary of reported patients, who developed neuralgic amyotrophy after vaccination against SARS-CoV-2

Reference	Neurological complication	Country	Age/sex	Vaccine type	Duration after vaccination	Clinical features	Neuroimaging	Treatment	Outcome
Mahajan et al. [128]	Parsonage-Turner syndrome	USA	50/M	COVID-19 BNT162b2 vaccination	7 days	Sudden onset of severe left periscapular pain after first dose. One week after the second dose, the patient developed left hand grip and left wrist extension weakness. Electromyography showed decreased motor unit recruitment	Normal	Corticosteroids	Improved
Diaz-Segarra et al. [129]	Painless idiopathic neuralgic amyotrophy	USA	35/F	Pfizer-BioNTech COVID-19 vaccine	9 days	New-onset painless left arm weakness, numbness, and paresthesias	Cervical spine computed tomography showed mild degenerative changes without foraminal narrowing	High-dose prednisone	Improved
Antonio Crespo Buriello et al. [130]	Parsonage-Turner syndrome	Spain	38/M	Vaxzevria (AstraZeneca)	4 days	Shoulder and arm pain. Electrophysiology suggested brachial plexopathy	MRI of the shoulder revealed a mild left subacromial tendinopathy	Methylprednisolone	Improved

Table 9 Summary of reported patients, who developed Herpes zoster after vaccination against SARS-CoV-2

Reference	Neurological complication	Country	Age/sex	Vaccine type	Duration after vaccination	Clinical features	Neuroimaging	Treatment	Outcome
Tessas and Kluger [134]	Herpes zoster	Finland	44/M	BNT162b2 mRNA COVID-19 vaccine	7 days	Herpetiform vesicular and erythematous rash on the left upper back	None	Oral valacyclovir	Improved
Rodríguez-Jiménez et al. [135] A report of 5 cases	Herpes zoster	Spain	39–58 F=3	BNT162b2 mRNA COVID-19 vaccine (Pfizer)	1–16 (4 less than 7 days)	Painful herpetiform dermatomal rash	None	None	None
Eid et al. [136]	Herpes zoster	Lebanon	79/M	mRNA COVID vaccine	6 days	Painful herpetiform dermatomal rash	None	Antiviral treatment	Improved
Bostan and Yalici-Armagan [137]	Herpes zoster	Turkey	78/M	Inactivated COVID-19 vaccine		Erythematous, painful, and pruritic lesions on chest			
Furer et al. [138] (a report of 6 cases)	Herpes zoster	Israel	36–61 All females	BNT162b2 mRNA vaccination	3–14 days	All had autoimmune inflammatory rheumatic diseases	Not done	NA	NA
Aksu and Öztürk et al. [139]	Herpes zoster	Turkey	68/M	The inactivated COVID-19 vaccine	5 days	Herpes zoster ophthalmicus in one Truncal herpes zoster in others multiple pinheaded vesicular lesions upon an erythematous base occupying an area on his right mammary region and back corresponding to T3–T5 dermatomes	Not done	Valacyclovir paracetamol	Improved
Chiu et al. [140] (a report of 3 cases)	Herpes zoster	Taiwan	71/M 46/M 42/M	Pfizer-BNT162b2 mRNA and Moderna mRNA-1273	2 days 7 days 2 days	Erythematous papules and vesicle in dermatomal pattern	Not done	Oral acyclovir	All improved
Alpalhão and Filipe et al. [141] (a report of 4 cases)	Herpes zoster	Portugal	NA	Pfizer's Comirnaty™ vaccine AstraZeneca Vaxzevria™ vaccine	3–6 days	Erythematous papules and vesicle in dermatomal pattern	Not done	Valacyclovir	All improved
Channa et al. [142]	Herpes zoster	USA	81/M	mRNA-1273 (Moderna) Covid-19 vaccine	3 days	A dermatomal rash	Not done	Not available	Not available

Table 10 Summary of reported patients, who developed an acute muscular disorder following vaccination against SARS-CoV-2

Reference	Neurological complication	Country	Age/sex	Vaccine type	Duration after vaccination	Clinical features	Neuroimaging	Treatment	Outcome
Tan et al. [143]	Rhabdomyolysis in a patient with Carnitine palmitoyltransferase II deficiency	UK	27/M	COVID-19 vaccine AstraZeneca	5 h	Fever, vomiting, shortness of breath, frank hematuria, and myalgia CK concentration of 105,000 U/L and deranged liver function tests (ALT 300 U/L and AST 1496 U/L)	None	Continuous intravenous dextrose 10% and a high carbohydrate diet	Improved
Mack et al. [144]	Rhabdomyolysis	USA	80/M	Second dose of Moderna COVID-19 vaccine	2 days	Generalized body aches, nausea, and vomiting elevated CK	None	IV fluids	Improved
Nassar et al. [145]	Rhabdomyolysis	USA	21/M	First Pfizer/BioNTech COVID-19 vaccine	1 day	Severe back pain with radiation to his left lateral thigh Creatinine phosphokinase (CPK) level more than 22,000 U/L	Normal	IV fluids	Improved
Theodorou et al. [146]	Myositis	Greece	56/F	Modified mRNA COVID-19 vaccine	8 days after second dose	There was tenderness over the deltoid muscle, guarding, and decreased abduction of the shoulder and arm along with elevated CPK	On MRI, the deltoid muscle was edematous. On contrast enhancement, muscle exhibited enhancement indicating inflammation	Symptomatic	Improved
Godoy et al. [147]	Myositis ossificans	Brazil	51/M		3 months	Right upper arm pain, soreness and palpable mass	Intramuscular nodule in the proximal fibers of the brachii muscle with perilesional muscle edema One week later, CT showed a hypoattenuating intramuscular nodule with internal calcifications	NSAIDs	Improved

Post-vaccination Guillain-Barré syndrome generally affects older adults within 2 weeks of vaccine administration. Clinical presentation is similar to acute demyelinating neuropathy; nerve conduction studies show demyelinating pattern, and CSF examination shows cyto-albuminic dissociation. Many patients present only with facial diplegia. Response to immunotherapy is generally good. (Table 7) [110–126].

Proposed pathogenesis of Guillain-Barré syndrome is an autoantibody-mediated immunological damage of peripheral nerves via mechanism of molecular mimicry between structural components of peripheral nerves and the microorganism. Lately, several cases of Guillain-Barré syndrome following COVID-19 vaccination have also been reported.

Small fiber neuropathy

Waheed et al. described a 57-year-old female, who presented with painful neuropathy following administration of the mRNA COVID-19 vaccine. Patient subacutely presented with intense peripheral burning sensations. Electrodiagnostic studies were normal. Skin biopsy proved small fiber neuropathy. Patient responded to gabapentin. (Table 7) [127].

Parsonage-Turner syndrome

Parsonage-Turner syndrome or neuralgic amyotrophy is clinically manifested with acute unilateral shoulder pain followed by brachial plexopathy. Parsonage-Turner syndrome is usually triggered by any infection, surgery, or rarely vaccination. In many reports, Parsonage-Turner syndrome has been described following COVID-19 vaccination. (Table 8) [128–130].

Herpes zoster

Herpes zoster occurs following reactivation of varicella zoster virus. Patients with herpes zoster present with the classic maculopapular rash, which is unilateral, confined to a single dermatome. The rash disappears in 7 to 10 days. Postherpetic neuralgia is the frequent complication of herpes zoster, which is noted in 1 in 5 patients. McMahon and co-workers recorded 414 cutaneous reactions to mRNA COVID-19 vaccines, and 5 (1.9%) were diagnosed with herpes zoster [131]. Other types of COVID-19 vaccines are infrequently associated with post-vaccination reactivation of herpes zoster. It has been suggested that vaccine-induced immunomodulation, resulting in dysregulation of T cell function, is responsible for reactivation of herpes zoster virus [132, 133]. Reports of herpes zoster reactivation after vaccine against SARS-CoV-2 are summarized in Table 9 [134–142].

Myositis and rhabdomyolysis

There are reports, which have indicated that COVID-19 vaccines have potential to damage the skeletal muscles as well (Table 10) [143–147]. Tan and colleagues described a patient with a known carnitine palmitoyltransferase-II deficiency disorder, who developed fever, vomiting, shortness of breath, frank haematuria, myalgia and muscle weakness within four hours of receiving AstraZeneca COVID-19 vaccine [143]. Theodorou and colleagues described a 56-year-old woman who, 8 days after a second dose of vaccine administration, developed severe left upper arm pain along restricted shoulder movements. Her serum creatine kinase was elevated suggesting skeletal muscle damage. MRI revealed severely edematous deltoid muscles. Contrast-enhanced imaging demonstrated enhancement of deltoid muscles suggestive of myositis [146].

Conclusion

Post-authorization, a wide spectrum of serious neurological complications has been reported following COVID-19 vaccination. The most devastating neurological complication is cerebral venous sinus thrombosis that has been reported in females of childbearing age following adenovector-based vaccines. Another major neurological complication of concern is Bell's palsy that was reported dominantly following mRNA vaccine administration. Transverse myelitis, acute disseminated encephalomyelitis, and Guillain-Barré syndrome are other severe unexpected post-vaccination complications that can occur as result of molecular mimicry and subsequent neuronal damage. Most of other serious neurological complications are reported in either in form of isolated case reports or small cases series. A causal association of these adverse events is controversial; large collaborative prospective studies are needed to prove causality.

Declarations

Ethical approval None

Conflict of interest The authors declare no competing interests.

References

1. World Health Organization. 12 January 2021. WHO Coronavirus (COVID-19) Dashboard. &It; The World Health Organization <https://covid19.who.int/>. Accessed 1 Aug 2021.

2. Jeff Craven. 10 June 2021. COVID-19 vaccine tracker. &It; <https://www.raps.org/news-and-articles/news-articles/2020/3/covid-19-vaccine-tracker>. Accessed 16 June 2021.
3. Piyasirisilp S, Hemachudha T (2002) Neurological adverse events associated with vaccination. *Curr Opin Neurol* 15(3):333–338
4. Hause AM, Gee J, Johnson T et al (2021) Anxiety-related adverse event clusters after Janssen COVID-19 vaccination - five U.S. mass vaccination sites, April 2021. *MMWR Morb Mortal Wkly Rep* 70(18):685–688
5. García-Grimshaw M, Ceballos-Liceaga SE, Hernández-Vanegas LE et al (2021) Neurologic adverse events among 704,003 first-dose recipients of the BNT162b2 mRNA COVID-19 vaccine in Mexico: a nationwide descriptive study. *Clin Immunol* 229:108786
6. Kim SH, Wi YM, Yun SY et al (2021) Adverse events in healthcare workers after the first dose of ChAdOx1 nCoV-19 or BNT162b2 mRNA COVID-19 vaccination: a single center experience. *J Korean Med Sci* 36(14):e107
7. Lee YW, Lim SY, Lee JH et al (2021) Adverse reactions of the second dose of the BNT162b2 mRNA COVID-19 vaccine in healthcare workers in Korea. *J Korean Med Sci*. 36(21):e153
8. Göbel CH, Heinze A, Karstedt S, et al. 2021 Headache attributed to vaccination against COVID-19 (coronavirus SARS-CoV-2) with the ChAdOx1 nCoV-19 (AZD1222) vaccine: a multicenter observational cohort study [published online ahead of print, 2021 Jul 27]. *Pain Ther*. 1–22.
9. Module 3. Adverse events following immunization. https://www.who.int/vaccine_safety/initiative/tech_support/Part-3.pdf?ua=1. Accessed 19 June 2021.
10. Ng JH, Chaudhuri KR, Tan EK (2021) Functional neurological disorders and COVID-19 vaccination. *Ann Neurol* 90(2):328
11. Kim DD, Kung CS, Perez DL (2021) Helping the public understand adverse events associated with COVID-19 vaccinations: lessons learned from functional neurological disorder. *JAMA Neurol* 78(7):789–790
12. Butler M, Coebergh J, Safavi F, et al. 2021 Functional neurological disorder after SARS-CoV-2 vaccines: two case reports and discussion of potential public health implications [published online ahead of print, 2021 Jul 15]. *J Neuropsychiatry Clin Neurosci*. [appineuropsych21050116](https://doi.org/10.1176/appi.neuropsych.21050116). <https://doi.org/10.1176/appi.neuropsych.21050116>
13. Ercoli T, Lutzoni L, Orofino G, Muroli A, Defazio G. 2021 Functional neurological disorder after COVID-19 vaccination [published online ahead of print, 2021 Jul 29]. *Neurol Sci*.;1–2. <https://doi.org/10.1007/s10072-021-05504-8>
14. Iba T, Levy JH, Warkentin TE. 2021 Recognizing vaccine-induced immune thrombotic thrombocytopenia [published online ahead of print, 2021 Jul 13]. *Crit Care Med*. <https://doi.org/10.1097/CCM.0000000000005211>
15. Pomara C, Sessa F, Ciaccio M, et al. 2021 Post-mortem findings in vaccine-induced thrombotic thrombocytopenia [published online ahead of print, 2021 May 20]. *Haematologica*. <https://doi.org/10.3324/haematol.2021.279075>.
16. Ledford H (2021) COVID vaccines and blood clots: five key questions. *Nature* 592(7855):495–496
17. McGonagle D, De Marco G, Bridgewood C (2021) Mechanisms of Immunothrombosis in vaccine-induced thrombotic thrombocytopenia (VITT) compared to natural SARS-CoV-2 Infection. *J Autoimmun* 121:102662
18. Castelli GP, Pognani C, Sozzi C, Franchini M, Vivona L (2021) Cerebral venous sinus thrombosis associated with thrombocytopenia post-vaccination for COVID-19. *Crit Care* 25(1):137. <https://doi.org/10.1186/s13054-021-03572-y>
19. D'Agostino V, Caranci F, Negro A et al (2021) A rare case of cerebral venous thrombosis and disseminated intravascular coagulation temporally associated to the COVID-19 vaccine administration. *J Pers Med* 11(4):285. <https://doi.org/10.3390/jpm11040285>
20. Scully M, Singh D, Lown R et al (2021) Pathologic antibodies to platelet factor 4 after ChAdOx1 nCoV-19 vaccination. *N Engl J Med* 384(23):2202–2211. <https://doi.org/10.1056/NEJMoa210538512>
21. Franchini M, Testa S, Pezzo M et al (2021) Cerebral venous thrombosis and thrombocytopenia post-COVID-19 vaccination. *Thromb Res* 202:182–183. <https://doi.org/10.1016/j.thromres.2021.04.001>
22. Mehta PR, Apap Mangion S, Bengner M et al (2021) Cerebral venous sinus thrombosis and thrombocytopenia after COVID-19 vaccination - a report of two UK cases. *Brain Behav Immun* 95:514–517. <https://doi.org/10.1016/j.bbi.2021.04.006.11>
23. Bersinger S, Lagarde K, Marlu R, Pernod G, Payen JF (2021) Using nonheparin anticoagulant to treat a near-fatal case with multiple venous thrombotic lesions during ChAdOx1 nCoV-19 vaccination-related vaccine-induced immune thrombotic thrombocytopenia. *Crit Care Med* 49(9):e870–e873. <https://doi.org/10.1097/CCM.00000000000005105>
24. Ramdeny S, Lang A, Al-Izzi S, Hung A, Anwar I, Kumar P. Management of a patient with a rare congenital limb malformation syndrome after SARS-CoV-2 vaccine-induced thrombosis and thrombocytopenia (VITT) [published online ahead of print, 2021 Jun 7]. *Br J Haematol*. 2021. <https://doi.org/10.1111/bjh.17619>.
25. Zakaria Z, Sapiai NA, Ghani ARI (2021) Cerebral venous sinus thrombosis 2 weeks after the first dose of mRNA SARS-CoV-2 vaccine. *Acta Neurochir (Wien)* 163(8):2359–2362. <https://doi.org/10.1007/s00701-021-04860-w>
26. Ryan E, Benjamin D, McDonald I et al (2021) AZD1222 vaccine-related coagulopathy and thrombocytopenia without thrombosis in a young female. *Br J Haematol* 194(3):553–556. <https://doi.org/10.1111/bjh.17530>
27. Graf T, Thiele T, Klingebiel R, Greinacher A, Schäbitz WR, Greeve I. 2021 Immediate high-dose intravenous immunoglobulins followed by direct thrombin-inhibitor treatment is crucial for survival in Sars-Covid-19-adenoviral vector vaccine-induced immune thrombotic thrombocytopenia VITT with cerebral sinus venous and portal vein thrombosis [published online ahead of print, May 22]. *J Neurol*. 2021;1–3. <https://doi.org/10.1007/s00415-021-10599-2>
28. George G, Friedman KD, Curtis BR, Lind SE. 2021 Successful treatment of thrombotic thrombocytopenia with cerebral sinus venous thrombosis following Ad26.COV2.S vaccination [published online ahead of print, 2021 May 14]. *Am J Hematol*. <https://doi.org/10.1002/ajh.26237>.
29. Jamme M, Mosnino E, Hayon J, Franchineau G (2021) Fatal cerebral venous sinus thrombosis after COVID-19 vaccination. *Intensive Care Med* 47(7):790–791. <https://doi.org/10.1007/s00134-021-06425-y>
30. Tiede A, Sachs UJ, Czwalińska A, et al. Prothrombotic immune thrombocytopenia after COVID-19 vaccine [published online ahead of print, 2021 Apr 28]. *Blood*. 2021;blood.2021011958. <https://doi.org/10.1182/blood.2021011958>. 13
31. Schulz JB, Berlit P, Diener HC, Gerloff C, Greinacher A, Klein C. 2021 COVID-19 vaccine-associated cerebral venous thrombosis in Germany. medRxiv.04.30.21256383; doi: <https://doi.org/10.1101/2021.04.30.21256383>. 14
32. Bourguignon A, Arnold DM, Warkentin TE, et al. 2021 Adjunct immune globulin for vaccine-induced thrombotic thrombocytopenia [published online ahead of print, 2021 Jun 9]. *N Engl J Med*. <https://doi.org/10.1056/NEJMoa2107051>.
33. Gattringer T, Gressenberger P, Gary T, Wöflfer A, Kneihsl M, Raggam RB. 2021 Successful management of vaccine-induced immune thrombotic thrombocytopenia-related cerebral sinus

- venous thrombosis after ChAdOx1 nCov-19 vaccination [published online ahead of print, 2021 Jul 8]. *Stroke Vasc Neurol*. svn-2021-001142. <https://doi.org/10.1136/svn-2021-001142>
34. Ikenberg B, Demleitner AF, Thiele T et al (2021) Cerebral venous sinus thrombosis after ChAdOx1 nCov-19 vaccination with a misleading first cerebral MRI scan. *Stroke Vasc Neurol* 8:svn-2021-001095. <https://doi.org/10.1136/svn-2021-001095>
 35. Clark RT, Johnson L, Billotti J et al (2021) Early outcomes of bivalirudin therapy for thrombotic thrombocytopenia and cerebral venous sinus thrombosis after Ad26.COV2.S vaccination. *Ann Emerg Med* S0196 0644(21):00342 5. <https://doi.org/10.1016/j.annemergmed.2021.04.035>
 36. Bonato S, Artoni A, Lecchi A, et al. 2021 Massive cerebral venous thrombosis due to vaccine-induced immune thrombotic thrombocytopenia [published online ahead of print, 2021 Jul 15]. *Haematologica*. <https://doi.org/10.3324/haematol.2021.279246>
 37. Wang RL, Chiang WF, Shyu HY et al (2021) COVID-19 vaccine-associated acute cerebral venous thrombosis and pulmonary artery embolism. *QJM* 10:hcab185. <https://doi.org/10.1093/qjmed/hcab185>
 38. Dutta A, Ghosh R, Bhattacharya D et al (2021) Anti-PF4 antibody negative cerebral venous sinus thrombosis without thrombocytopenia following immunization with COVID-19 vaccine in an elderly non-comorbid Indian male, managed with conventional heparin-warfarin based anticoagulation. *Diabetes Metab Syndr* 15(4):102184. <https://doi.org/10.1016/j.dsx.2021.06.021>
 39. Aladdin Y, Algahtani H, Shirah B (2021) Vaccine-induced immune thrombotic thrombocytopenia with disseminated intravascular coagulation and death following the ChAdOx1 nCoV-19 Vaccine. *J Stroke Cerebrovasc Dis* 30(9):105938. <https://doi.org/10.1016/j.jstrokecerebrovasdis.2021.105938>
 40. Lavin M, Elder PT, O'Keeffe D, et al. Vaccine-induced immune thrombotic thrombocytopenia (VITT) - a novel clinico-pathological entity with heterogeneous clinical presentations [published online ahead of print, 2021 Jun 22]. *Br J Haematol*. 2021. <https://doi.org/10.1111/bjh.17613>.
 41. Tølbøll Sørensen AL, Rolland M, Hartmann J et al (2021) A case of thrombocytopenia and multiple thromboses after vaccination with ChAdOx1 nCoV-19 against SARS-CoV-2. *Blood Adv* 5(12):2569–2574. <https://doi.org/10.1182/bloodadvances.2021004904>
 42. Fan BE, Shen JY, Lim XR et al (2021) Cerebral venous thrombosis post BNT162b2 mRNA SARS-CoV-2 vaccination: a black swan event. *Am J Hematol* 96(9):E357–E361. <https://doi.org/10.1002/ajh.26272>
 43. Suresh P, Petchey W (2021) ChAdOx1 nCOV-19 vaccine-induced immune thrombotic thrombocytopenia and cerebral venous sinus thrombosis (CVST). *BMJ Case Rep* 14(6):e243931. <https://doi.org/10.1136/bcr-2021-243931>
 44. Dias L, Soares-Dos-Reis R, Meira J et al (2021) Cerebral venous thrombosis after BNT162b2 mRNA SARS-CoV-2 vaccine. *J Stroke Cerebrovasc Dis* 30(8):105906. <https://doi.org/10.1016/j.jstrokecerebrovasdis.2021.105906>
 45. Guan CY, Tsai SH, Fan JS, Lin YK, Kao CC. 2021 A rare case of a middle-age Asian male with cerebral venous thrombosis after COVID-19 AstraZeneca vaccination [published online ahead of print, Jul 8]. *Am J Emerg Med*. 2021;S0735-6757(21)00571-4. <https://doi.org/10.1016/j.ajem.2021.07.011>
 46. Varona JF, García-Isidro M, Moeinvaziri M, Ramos-López M, Fernández-Domínguez M. 2021 Primary adrenal insufficiency associated with Oxford-AstraZeneca ChAdOx1 nCoV-19 vaccine-induced immune thrombotic thrombocytopenia (VITT) [published online ahead of print, Jul 10]. *Eur J Intern Med*. 2021;S0953-6205(21)00236-3. <https://doi.org/10.1016/j.ejim.2021.06.025>
 47. Pottgård A, Lund LC, Karlstad Ø et al (2021) Arterial events, venous thromboembolism, thrombocytopenia, and bleeding after vaccination with Oxford-AstraZeneca ChAdOx1-S in Denmark and Norway: population based cohort study. *BMJ* 373:n1114. <https://doi.org/10.1136/bmj.n1114>
 48. Krzywicka K, Heldner MR, Sánchez van Kammen M et al (2021) Post-SARS-CoV-2-vaccination cerebral venous sinus thrombosis: an analysis of cases notified to the European Medicines Agency. *Eur J Neurol* 28(11):3656–3662. <https://doi.org/10.1111/ene.15029>
 49. National Institute for Health and Care Excellence. 29 July 2021. COVID-19 rapid guideline: vaccine-induced immune thrombocytopenia and thrombosis (VITT). &It; <https://www.nice.org.uk/guidance/ng200/resources/covid19-rapid-guideline-vaccine-induced-immune-thrombocytopenia-and-thrombosis-vitt-pdf-51036811744>. Accessed 2 Aug 2021.
 50. Krzywicka K, Heldner MR, Sánchez van Kammen M et al (2021) Post-SARS-CoV-2-vaccination cerebral venous sinus thrombosis: an analysis of cases notified to the European Medicines Agency. *Eur J Neurol* 28(11):3656 3662. <https://doi.org/10.1111/ene.15029>
 51. Bersinger S, Lagarde K, Marlu R, Pernod G, Payen JF (2021) Using nonheparin anticoagulant to treat a near-fatal case with multiple venous thrombotic lesions during ChAdOx1 nCoV-19 vaccination-related vaccine-induced immune thrombotic thrombocytopenia. *Crit Care Med* 49(9):e870–e873. <https://doi.org/10.1097/CCM.0000000000005105>
 52. Simpson CR, Shi T, Vasileiou E et al (2021) First-dose ChAdOx1 and BNT162b2 COVID-19 vaccines and thrombocytopenic, thromboembolic and hemorrhagic events in Scotland. *Nat Med* 27(7):1290–1297. <https://doi.org/10.1038/s41591-021-01408-4>
 53. Athyros VG, Doumas M. 2021 A possible case of hypertensive crisis with intracranial haemorrhage after an mRNA Anti-COVID-19 vaccine [published online ahead of print, 2021 May 21]. *Angiology*.;33197211018323. <https://doi.org/10.1177/00033197211018323>
 54. Bjørnstad-Tuveng TH, Rudjord A, Anker P. 2021 Fatal cerebral haemorrhage after COVID-19 vaccine. *Fatal hjerneblødning etter covid-19-vaksine*. *Tidsskr Nor Lægeforen*. 2021;141. <https://doi.org/10.4045/tidsskr.21.0312>.
 55. de Mélo Silva ML Jr, Lopes DP. 2021 Large hemorrhagic stroke after ChAdOx1 nCoV-19 vaccination: a case report [published online ahead of print, 2021 Jul 17]. *Acta Neurol Scand*. <https://doi.org/10.1111/ane.13505>.
 56. Bayas A, Menacher M, Christ M, Behrens L, Rank A, Naumann M (2021) Bilateral superior ophthalmic vein thrombosis, ischaemic stroke, and immune thrombocytopenia after ChAdOx1 nCoV-19 vaccination. *Lancet* 397(10285):e11. [https://doi.org/10.1016/S0140-6736\(21\)00872-2](https://doi.org/10.1016/S0140-6736(21)00872-2)
 57. Al-Mayhani T, Saber S, Stubbs MJ et al (2021) Ischaemic stroke as a presenting feature of ChAdOx1 nCoV-19 vaccine-induced immune thrombotic thrombocytopenia. *J Neurol Neurosurg Psychiatry* 92(11):1247–1248. <https://doi.org/10.1136/jnnp-2021-326984>
 58. Blauenfeldt RA, Kristensen SR, Ernsten SL, Kristensen CCH, Simonsen CZ, Hvas AM (2021) Thrombocytopenia with acute ischemic stroke and bleeding in a patient newly vaccinated with an adenoviral vector-based COVID-19 vaccine. *J Thromb Haemost* 19(7):1771–1775. <https://doi.org/10.1111/jth.15347>
 59. Malik B, Kalantary A, Rikabi K, Kunadi A (2021) Pulmonary embolism, transient ischaemic attack and thrombocytopenia after the Johnson & Johnson COVID-19 vaccine. *BMJ Case Rep*. 14(7):e243975. <https://doi.org/10.1136/bcr-2021-243975>
 60. Finsterer J, Korn M. 2021 Aphasia seven days after second dose of an mRNA-based SARS-CoV-2 vaccine [published online

- ahead of print, 2021 Jun 24]. *Brain Hemorrhages*. <https://doi.org/10.1016/j.hest.2021.06.001>.
61. Walter U, Fuchs M, Grossmann A, et al. 2021 Adenovirus-vectored COVID-19 vaccine-induced immune thrombosis of carotid artery: a case report [published online ahead of print, 2021 Jul 26]. *Neurology*. <https://doi.org/10.1212/WNL.00000000000012576>.
 62. Baldelli L, Amore G, Montini A et al (2021) Hyperacute reversible encephalopathy related to cytokine storm following COVID-19 vaccine. *J Neuroimmunol* 358:577661. <https://doi.org/10.1016/j.jneuroim.2021.577661>
 63. Aladdin Y, Shirah B (2021) New-onset refractory status epilepticus following the ChAdOx1 nCoV-19 vaccine. *J Neuroimmunol* 357:577629. <https://doi.org/10.1016/j.jneuroim.2021.577629>
 64. Ghosh R, Dubey S, Roy D, Mandal A, Naga D, Benito-León J (2021) Focal onset non-motor seizure following COVID-19 vaccination: a mere coincidence? *Diabetes Metab Syndr* 15(3):1023–1024. <https://doi.org/10.1016/j.dsx.2021.05.003>
 65. Liu BD, Ugloini C, Jha P (2021) Two cases of post-Moderna COVID-19 vaccine encephalopathy associated with nonconvulsive status epilepticus. *Cureus* 13(7):e16172. <https://doi.org/10.7759/cureus.16172>
 66. Naharci MI, Tasci I. 2021 Delirium in a patient with Alzheimer's dementia following COVID-19 vaccination [published online ahead of print, 2021 Jul 10]. *Psychogeriatrics*. <https://doi.org/10.1111/psyg.12747>.
 67. Salinas MR, Dieppa M (2021) Transient akathisia after the SARS-Cov-2 vaccine. *Clin Park Relat Disord* 4:100098. <https://doi.org/10.1016/j.prdoa.2021.100098>
 68. Zavala-Jonguitud LF, Pérez-García CC (2021) Delirium triggered by COVID-19 vaccine in an elderly patient. *Geriatr Gerontol Int* 21(6):540. <https://doi.org/10.1111/ggi.14163>
 69. Alfishawy M, Bitar Z, Elgazzar A, Elzouairy M. 2021 Neuroleptic malignant syndrome following COVID-19 vaccination [published online ahead of print, Feb 20]. *Am J Emerg Med*. 2021;S0735–6757(21)00117–0. <https://doi.org/10.1016/j.ajem.2021.02.011>
 70. Ozgen Kenangil G, Ari BC, Guler C, Demir MK (2021) Acute disseminated encephalomyelitis-like presentation after an inactivated coronavirus vaccine. *Acta Neurol Belg* 121(4):1089–1091. <https://doi.org/10.1007/s13760-021-01699-x>
 71. Cao L, Ren L (2021) Acute disseminated encephalomyelitis after severe acute respiratory syndrome coronavirus 2 vaccination: a case report. *Acta Neurol Belg* 1:1–3. <https://doi.org/10.1007/s13760-021-01608-2>
 72. Raknuzzaman M, Jannaty T, Hossain MB, Saha B, Dey SK, Shahidullah M. 2021 Post Covid 19 vaccination acute disseminated encephalomyelitis: a case report in Bangladesh. *Int J Med Sci Clin Res Studies* 3. <https://doi.org/10.47191/ijmscrs/v1-i3-01>
 73. Torrealba-Acosta G, Martin JC, Huttenbach Y et al (2021) Acute encephalitis, myoclonus and Sweet syndrome after mRNA-1273 vaccine. *BMJ Case Rep* 14(7):e243173. <https://doi.org/10.1136/bcr-2021-243173>
 74. Vogrig A, Janes F, Gigli GL (2021) Acute disseminated encephalomyelitis after SARS-CoV-2 vaccination. *Clin Neurol Neurosurg* 208:106839. <https://doi.org/10.1016/j.clineuro.2021.106839>
 75. Zuhorn F, Graf T, Klingebiel R, Schäbitz WR, Rogalewski A (2021) Postvaccinal encephalitis after ChAdOx1 nCov-19. *Ann Neurol* 90(3):506–511. <https://doi.org/10.1002/ana.26182>
 76. Pellegrino P, Carnovale C, Perrone V et al (2013) Acute disseminated encephalomyelitis onset: evaluation based on vaccine adverse events reporting systems. *PLoS One* 8(10):e77766. <https://doi.org/10.1371/journal.pone.0077766>
 77. Malhotra SH, Gupta P, Prabhu V, Garg RK, Dandu H, Agarwal V. COVID-19 vaccination-associated myelitis [published online ahead of print, 2021 Mar 31]. *QJM*. 2021;hcab069. <https://doi.org/10.1093/qjmed/hcab069>
 78. Fitzsimmons, William and Nance, Christopher S., Sudden onset of myelitis after COVID-19 vaccination: an under-recognized severe rare adverse event (May 5, 2021). Available at SSRN: <https://ssrn.com/abstract=3841558> or <https://doi.org/10.2139/ssrn.3841558>
 79. Tahir N, Koorapati G, Prasad S et al (2021) SARS-CoV-2 vaccination-induced transverse myelitis. *Cureus* 13(7):e16624. <https://doi.org/10.7759/cureus.16624>
 80. Pagenkopf C, Südmeyer M (2021) A case of longitudinally extensive transverse myelitis following vaccination against Covid-19. *J Neuroimmunol* 358:577606. <https://doi.org/10.1016/j.jneuroim.2021.577606>
 81. Helmchen C, Buttler GM, Markewitz R, Hummel K, Wiendl H, Boppel T. 2021 Acute bilateral optic/chiasm neuritis with longitudinal extensive transverse myelitis in longstanding stable multiple sclerosis following vector-based vaccination against the SARS-CoV-2 [published online ahead of print, Jun 15]. *J Neurol*. 2021;1–6. <https://doi.org/10.1007/s00415-021-10647-x>
 82. Havla J, Schultz Y, Zimmermann H, Hohlfeld R, Danek A, Kumpfel T. 2021 First manifestation of multiple sclerosis after immunization with the Pfizer-BioNTech COVID-19 vaccine [published online ahead of print, 2021 Jun 11]. *J Neurol*. 1–4. <https://doi.org/10.1007/s00415-021-10648-w>
 83. Chen S, Fan XR, He S, Zhang JW, Li SJ (2021) Watch out for neuromyelitis optica spectrum disorder after inactivated virus vaccination for COVID-19. *Neurol Sci* 42(9):3537–3539. <https://doi.org/10.1007/s10072-021-05427-4>
 84. Chagla Z (2021) In adults, the Oxford/AstraZeneca vaccine had 70% efficacy against COVID-19 >14 d after the 2nd dose. *Ann Intern Med* 174(3):JC29. <https://doi.org/10.7326/ACPJ202103160-029>
 85. Knoll MD, Wonodi C (2021) Oxford-AstraZeneca COVID-19 vaccine efficacy. *Lancet* 397(10269):72–74. [https://doi.org/10.1016/S0140-6736\(20\)32623-4](https://doi.org/10.1016/S0140-6736(20)32623-4)
 86. Román GC, Gracia F, Torres A, Palacios A, Gracia K, Harris D (2021) Acute transverse myelitis (ATM):clinical review of 43 patients with COVID-19-associated ATM and 3 post-vaccination ATM serious adverse events with the ChAdOx1 nCoV-19 vaccine (AZD1222). *Front Immunol* 26(12):653786. <https://doi.org/10.3389/fimmu.2021.653786>. PMID:33981305;PMCID:PMC8107358
 87. Shemer A, Pras E, Hecht I (2021) Peripheral facial nerve palsy following BNT162b2 (COVID-19) vaccination. *Isr Med Assoc J* 23(3):143–144 (PMID: 33734623)
 88. Repajic M, Lai XL, Xu P, Liu A (2021) Bell's Palsy after second dose of Pfizer COVID-19 vaccination in a patient with history of recurrent Bell's palsy. *Brain Behav Immun Health* 13:100217. <https://doi.org/10.1016/j.bbih.2021.100217>
 89. Colella G, Orlandi M, Cirillo N. 2021 Bell's palsy following COVID-19 vaccination [published online ahead of print, 2021 Feb 21]. *J Neurol*. 1–3. doi:<https://doi.org/10.1007/s00415-021-10462-4>
 90. Martin-Villares C, Vazquez-Feito A, Gonzalez-Gimeno MJ, de la Nogal-Fernandez B. 2021 Bell's palsy following a single dose of mRNA SARS-CoV-2 vaccine: a case report [published online ahead of print, 2021 May 25]. *J Neurol*. 1–2. doi:<https://doi.org/10.1007/s00415-021-10617-3>
 91. Nishizawa Y, Hoshina Y, Baker V. 2021 Bell's palsy following the Ad26.COV2.S COVID-19 vaccination [published online ahead of print, 2021 May 20]. *QJM*.;hcab143. doi:<https://doi.org/10.1093/qjmed/hcab143>
 92. Gómez de Terreros Caro G, Díaz SG, Alé MP, Gimeno LM. 2021 PARÁLISIS DE BELL TRAS VACUNACIÓN COVID19: A PROPÓSITO DE UN CASO [BELL'S PALSY FOLLOWING

- COVID-19 VACCINATION: A CASE REPORT] [published online ahead of print, 2021 Apr 12]. *Neurologia* (Engl Ed). <https://doi.org/10.1016/j.nrl.2021.04.004>.
93. Burrows A, Bartholomew T, Rudd J, Walker D (2021) Sequential contralateral facial nerve palsies following COVID-19 vaccination first and second doses. *BMJ Case Rep.* 14(7):e243829. <https://doi.org/10.1136/bcr-2021-243829>
 94. Obermann M, Krasniqi M, Ewers N, Fayad J, Haeberle U (2021) Bell's palsy following COVID-19 vaccination with high CSF antibody response. *Neurol Sci* 42(11):4397–4399. <https://doi.org/10.1007/s10072-021-05496-5>
 95. Iftikhar H, Noor SU, Masood M et al (2021) Bell's palsy after 24 hours of mRNA-1273 SARS-CoV-2 vaccine. *Cureus* 13(6):e15935. <https://doi.org/10.7759/cureus.15935>
 96. Ozonoff A, Nanishi E, Levy O (2021) Bell's palsy and SARS-CoV-2 vaccines-an unfolding story – authors' reply [published online ahead of print, 2021 Jun 7]. *Lancet Infect Dis* S1473–3099(21)00323–6. doi:[https://doi.org/10.1016/S1473-3099\(21\)00323-6](https://doi.org/10.1016/S1473-3099(21)00323-6)
 97. Shemer A, Pras E, Einan-Lifshitz A, Dubinsky-Pertzov B, Hecht I (2021) Association of COVID-19 vaccination and facial nerve palsy: a case-control study. *JAMA Otolaryngol Head Neck Surg* 147(8):739–743. <https://doi.org/10.1001/jamaoto.2021.1259>
 98. Ozonoff A, Nanishi E, Levy O (2021) Bell's palsy and SARS-CoV-2 vaccines. *Lancet Infect Dis* 21(4):450–452. [https://doi.org/10.1016/S1473-3099\(21\)00076-1](https://doi.org/10.1016/S1473-3099(21)00076-1)
 99. Konstantinidis I, Tsakiropoulou E, Hähner A, de With K, Poulas K, Hummel T (2021) Olfactory dysfunction after coronavirus disease 2019 (COVID-19) vaccination [published online ahead of print, 2021 May 28]. *Int Forum Allergy Rhinol.* <https://doi.org/10.1002/alr.22809>.
 100. Keir G, Maria NI, Kirsch CFE (2021) Unique imaging findings of neurologic phantoms following Pfizer-BioNTech COVID-19 vaccination: a case report. *Top Magn Reson Imaging* 30(3):133–137. <https://doi.org/10.1097/RMR.0000000000000287>
 101. Reyes-Capo DP, Stevens SM, Cavuoto KM (2021) Acute abducens nerve palsy following COVID-19 vaccination [published online ahead of print, 2021 May 24]. *J AAPOS* S1091–8531(21)00109–9. doi:<https://doi.org/10.1016/j.jaaapos.2021.05.003>
 102. Parrino D, Frosolini A, Gallo C, De Siati RD, Spinato G, de Filippis C (2021) Tinnitus following COVID-19 vaccination: report of three cases. *Int J Audiol* 13:1–4
 103. Tseng PT, Chen TY, Sun YS, Chen YW, Chen JJ (2021) The reversible tinnitus and cochleopathy followed first-dose AstraZeneca COVID-19 vaccination [published online ahead of print, 2021 Jul 23]. *QJM hcab210*. doi:<https://doi.org/10.1093/qjmed/hcab210>
 104. Narasimhalu K, Lee WC, Salkade PR, De Silva DA (2021) Trigeminal and cervical radiculitis after tozinameran vaccination against COVID-19. *BMJ Case Rep* 14(6):e242344. <https://doi.org/10.1136/bcr-2021-242344>
 105. Wichova H, Miller ME, Derebery MJ (2021) Otolologic manifestations after COVID-19 vaccination: the house ear clinic experience. *Otol Neurotol* 42(9):e1213–e1218. <https://doi.org/10.1097/MAO.00000000000003275>
 106. Santovito LS, Pinna G (2021) Acute reduction of visual acuity and visual field after Pfizer-BioNTech COVID-19 vaccine 2nd dose: a case report. *Inflamm Res* 70(9):931–933. <https://doi.org/10.1007/s00011-021-01476-9>
 107. Dyer O (2021) Covid-19: Regulators warn that rare Guillain-Barré cases may link to J&J and AstraZeneca vaccines. *BMJ* 374:n1786. <https://doi.org/10.1136/bmj.n1786>
 108. Márquez Loza AM, Holroyd KB, Johnson SA, Pilgrim DM, Amato AA (2021) Guillain-Barré syndrome in the placebo and active arms of a COVID-19 vaccine clinical trial: temporal associations do not imply causality [published online ahead of print, 2021 Apr 6]. *Neurology.* 2021. <https://doi.org/10.1212/WNL.0000000000011881>.
 109. FDA Briefing Document Janssen Ad26.COV2.S Vaccine for the prevention of COVID-19.26 February 2021. Vaccines and Related Biological Products Advisory Committee Meeting. &It; <https://www.fda.gov/media/146217/download>. Accessed 24 June 2021
 110. Waheed S, Bayas A, Hindi F, Rizvi Z, Espinosa PS (2021) Neurological complications of COVID-19: Guillain-Barre syndrome following Pfizer COVID-19 vaccine. *Cureus.* 13(2):e13426. <https://doi.org/10.7759/cureus.13426>
 111. Márquez Loza AM, Holroyd KB, Johnson SA, Pilgrim DM, Amato AA (2021) Guillain-Barré syndrome in the placebo and active arms of a COVID-19 vaccine clinical trial: temporal associations do not imply causality [published online ahead of print, 2021 Apr 6]. *Neurology.* <https://doi.org/10.1212/WNL.0000000000011881>.
 112. Patel SU, Khurram R, Lakhani A, Quirk B (2021) Guillain-Barre syndrome following the first dose of the chimpanzee adenovirus-vectored COVID-19 vaccine, ChAdOx1. *BMJ Case Rep.* 14(4):e242956. <https://doi.org/10.1136/bcr-2021-242956>
 113. Razok A, Shams A, Almeer A et al (2021) Post-COVID-19 vaccine Guillain-Barré syndrome; first reported case from Qatar. *Authorea.* May 07,. DOI: <https://doi.org/10.22541/au.162041666.65803989/v1>
 114. Ogbobor O, Seth H, Min Z, Bhanot N (2021) Guillain-Barré syndrome following the first dose of SARS-CoV-2 vaccine: a temporal occurrence, not a causal association. *IDCases* 24:e01143. <https://doi.org/10.1016/j.idcr.2021.e01143>
 115. Finsterer J (2021) Exacerbating Guillain-Barré syndrome eight days after vector-based COVID-19 vaccination. *Case Rep Infect Dis* 2021:3619131. <https://doi.org/10.1155/2021/3619131>
 116. Maramattom BV, Krishnan P, Paul R et al (2021) Guillain-Barré syndrome following ChAdOx1-S/nCoV-19 vaccine. *Ann Neurol* 90(2):312–314. <https://doi.org/10.1002/ana.26143>
 117. Allen CM, Ramsamy S, Tarr AW, Tighe PJ, Irving WL, Tanasescu R, Evans JR (2021) Guillain-Barré syndrome variant occurring after SARS-CoV-2 vaccination. *Ann Neurol.* <https://doi.org/10.1002/ana.26144>
 118. Kohli S, Varshney M, Mangla S, Jaiswal B, Chhabra PH (2021) Guillain-Barré syndrome after COVID-19 vaccine: should we assume a causal Link? *International Journal of Medical and Pharmaceutical Case Reports* 14(1):20–24. <https://doi.org/10.9734/ijmpcr/2021/v14i130124>
 119. Azam S, Khalil A, Taha A (2021) Guillain-Barré syndrome in a 67-year-old male post COVID-19 vaccination (Astra Zeneca). *American Journal of Medical Case Reports* 9(8):424–427
 120. Hasan T, Khan M, Khan F, Hamza G (2021) Case of Guillain-Barré syndrome following COVID-19 vaccine. *BMJ Case Rep* 14(6):e243629. <https://doi.org/10.1136/bcr-2021-243629>
 121. Theuriet J, Richard C, Becker J, Pegat A, Bernard E, Vukusic S (2021) Guillain-Barré syndrome following first injection of ChAdOx1 nCoV-19 vaccine: First report. *Rev Neurol (Paris)* S0035–3787(21)00585–3 doi:<https://doi.org/10.1016/j.neurol.2021.04.005>
 122. Bonifacio GB, Patel D, Cook S, et al (2021) Bilateral facial weakness with paraesthesia variant of Guillain-Barré syndrome following Vaxzevria COVID-19 vaccine [published online ahead of print, 2021 Jul 14]. *J Neurol Neurosurg Psychiatry* jnnp-2021–327027. doi:<https://doi.org/10.1136/jnnp-2021-327027>
 123. Nasuelli NA, De Marchi F, Cecchin M et al (2021) A case of acute demyelinating polyradiculoneuropathy with bilateral facial palsy after ChAdOx1 nCoV-19 vaccine. *Neurol Sci* 42(11):4747–4749. <https://doi.org/10.1007/s10072-021-05467-w>
 124. Jain E, Pandav K, Regmi P et al (2021) Facial diplegia: a rare, atypical variant of Guillain-Barré syndrome and Ad26.COV2.S

- Vaccine. *Cureus* 13(7):e16612. <https://doi.org/10.7759/cureus.16612>
- 125 McKean N, Chircop C (2021) Guillain-Barré syndrome after COVID-19 vaccination. *BMJ Case Rep* 14(7):e244125. <https://doi.org/10.1136/bcr-2021-244125>
 - 126 Bonifacio GB, Patel D, Cook S, et al. 2021 Bilateral facial weakness with paraesthesia variant of Guillain-Barré syndrome following Vaxzevria COVID-19 vaccine [published online ahead of print, 2021 Jul 14]. *J Neurol Neurosurg Psychiatry* jnnp-2021-327027. doi:<https://doi.org/10.1136/jnnp-2021-327027>
 - 127 Waheed W, Carey ME, Tandan SR, Tandan R (2021) Post COVID-19 vaccine small fiber neuropathy. *Muscle Nerve* 64(1):E1–E2. <https://doi.org/10.1002/mus.27251>
 - 128 Mahajan S, Zhang F, Mahajan A, Zimnowodzki S (2021) Parsonage Turner syndrome after COVID-19 vaccination. *Muscle Nerve* 64(1):E3–E4. <https://doi.org/10.1002/mus.27255>
 - 129 Diaz-Segarra N, Edmond A, Gilbert C, Mckay O, Kloepping C, Yonclas P. 2021 Painless idiopathic neuralgic amyotrophy after COVID-19 vaccination: a case report [published online ahead of print, 2021 Apr 22]. *PM R*.<https://doi.org/10.1002/pmrj.12619>
 - 130 Antonio Crespo Burillo J, Martínez CL, Arguedas CG, Pueyo FJM (2021) Neuralgia amiotrófica secundaria a vacuna contra COVID-19 Vaxzevria (AstraZeneca) [Amyotrophic neuralgia secondary to Vaxzevria (AstraZeneca) COVID-19 vaccine]. *Neurología* 36(7):571–572. <https://doi.org/10.1016/j.nrl.2021.05.007>
 - 131 McMahon DE, Amerson E, Rosenbach M et al (2021) Cutaneous reactions reported after Moderna and Pfizer COVID-19 vaccination: a registry-based study of 414 cases. *J Am Acad Dermatol* 85(1):46–55. <https://doi.org/10.1016/j.jaad.2021.03.092>
 - 132 Arora P, Sardana K, Mathachan SR, Malhotra P. 2021 Herpes zoster after inactivated COVID-19 vaccine: a cutaneous adverse effect of the vaccine [published online ahead of print, 2021 Jun 2]. *J Cosmet Dermatol*. <https://doi.org/10.1111/jocd.14268>.
 - 133 Lladó I, Fernández-Bernáldez A, Rodríguez-Jiménez P 2021. "Varicella zoster virus reactivation and mRNA vaccines as a trigger". Reply to: Herpes-Zoster reactivation after mRNA-1273 (Moderna) SARS-CoV-2 Vaccination [published online ahead of print, 2021 Jul 22]. *JAAD Case Rep*. <https://doi.org/10.1016/j.jdcr.2021.07.011>.
 - 134 Tassis I, Kluger N (2021) Ipsilateral herpes zoster after the first dose of BNT162b2 mRNA COVID-19 vaccine. *J Eur Acad Dermatol Venereol* 35(10):e620–e622. <https://doi.org/10.1111/jdv.17422>
 - 135 Rodríguez-Jiménez P, Chicharro P, Cabrera LM et al (2021) Varicella-zoster virus reactivation after SARS-CoV-2 BNT162b2 mRNA vaccination: Report of 5 cases. *JAAD Case Rep* 12:58–59. <https://doi.org/10.1016/j.jdcr.2021.04.014>
 - 136 Eid E, Abdullah L, Kurban M, Abbas O (2021) Herpes zoster emergence following mRNA COVID-19 vaccine. *J Med Virol*. <https://doi.org/10.1002/jmv.27036>
 - 137 Bostan E, Yalici-Armagan B (2021) Herpes zoster following inactivated COVID-19 vaccine: a coexistence or coincidence? *J Cosmet Dermatol* 20(6):1566–1567. <https://doi.org/10.1111/jocd.14035>
 - 138 Furer V, Zisman D, Kibari A, Rimar D, Paran Y, Elkayam O. 2021 Herpes zoster following BNT162b2 mRNA Covid-19 vaccination in patients with autoimmune inflammatory rheumatic diseases: a case series [published online ahead of print, 2021 Apr 12]. *Rheumatology (Oxford)* keab345. doi:<https://doi.org/10.1093/rheumatology/keab345>
 - 139 Aksu SB, Öztürk GZ (2021) A rare case of shingles after COVID-19 vaccine: is it a possible adverse effect? *Clin Exp Vaccine Res* 10(2):198–201. <https://doi.org/10.7774/cevr.2021.10.2.198>
 - 140 Chiu HH, Wei KC, Chen A, Wang WH. 2021 Herpes zoster following COVID-19 vaccine: report of 3 cases [published online ahead of print, 2021 Jul 22]. *QJM*.<https://doi.org/10.1093/qjmed/hcab208>
 - 141 Alpalhão M, Filipe P (2021) Herpes Zoster following SARS-CoV-2 vaccination - a series of 4 cases. *J Eur Acad Dermatol Venereol* 35(11):e750–e752. <https://doi.org/10.1111/jdv.17555>
 - 142 Channa L, Torre K, Rothe M (2021) Letter to the editor: Herpes-Zoster reactivation after mRNA-1273 (Moderna) SARS-CoV-2 Vaccination. *JAAD Case Rep* 15:60–61. <https://doi.org/10.1016/j.jdcr.2021.05.042>
 - 143 Tan A, Stepien KM, Narayana STK (2021) Carnitine palmitoyltransferase II deficiency and post-COVID vaccination rhabdomyolysis. *QJM* 19:hcab077. <https://doi.org/10.1093/qjmed/hcab077>
 - 144 Mack M, Nichols L, Guerrero DM (2021) Rhabdomyolysis secondary to COVID-19 vaccination. *Cureus* 13(5):e15004. <https://doi.org/10.7759/cureus.15004>
 - 145 Nassar M, Chung H, Dhayaparan Y et al (2021) COVID-19 vaccine induced rhabdomyolysis: Case report with literature review. *Diabetes Metab Syndr*. 15(4):102170. <https://doi.org/10.1016/j.dsx.2021.06.007>
 - 146 Theodorou DJ, Theodorou SJ, Axiotis A, Gianniki M, Tsifetaki N (2021) COVID-19 vaccine-related myositis. *QJM* 1146(424):425. <https://doi.org/10.1093/qjmed/hcab043>
 - 147 Godoy IRB, Rodrigues TC, Skaf A (2021) Myositis ossificans following COVID-19 vaccination. *QJM* 9:hcab161. <https://doi.org/10.1093/qjmed/hcab161>

Publisher's note Springer Nature remains neutral with regard to jurisdictional claims in published maps and institutional affiliations.